

ISOI FELLOWSHIP/ DIPLOMATE SAMPLE CASE

NAME: DR JOEL B KHAN

ADDRESS:

MOBILE NO:

EMAIL ADDRESS:

Key Points for Case Submission

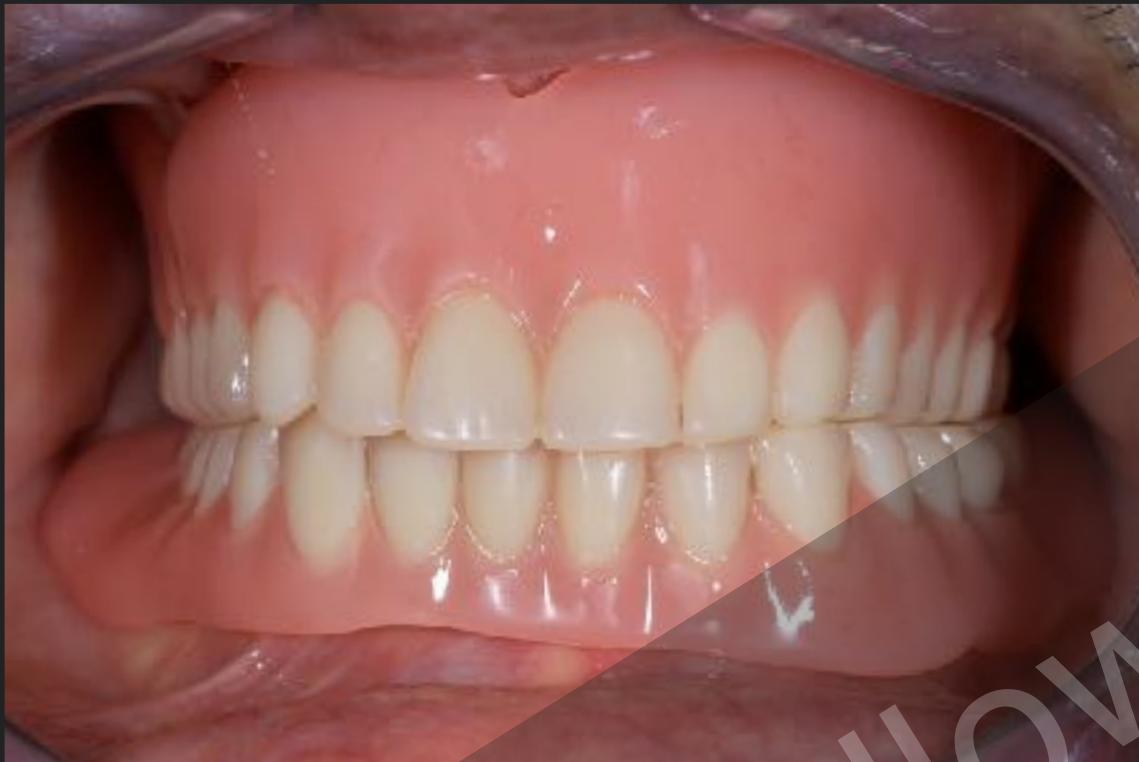- Please use this Powerpoint template without making any modifications
- Fellowship Applications need 10 Cases
- Diplomate Applications need 100 Cases (NOT 100 Implants) Including a minimum of 10 full arch cases and 5 Cases Demonstrating Bone Augmentation Procedure
- OPGs or Periapicals with good clarity (clearly showing the area of interest) are necessary
- Photos must be of diagnostic quality and clearly show the whole arches with soft tissues
- Date your photos and radiographs
- Make Sure you provide as much details as possible
- All your cases must be from different patients and must be restored and in function for a minimum of ONE year
- Save the file as 'yourname YYYY Fellowship/ Diplomate.ppt' (eg. JoelKhan 2018 Diplomate.ppt) and upload to isoi0050@gmail.com dropbox

CASE NO 1

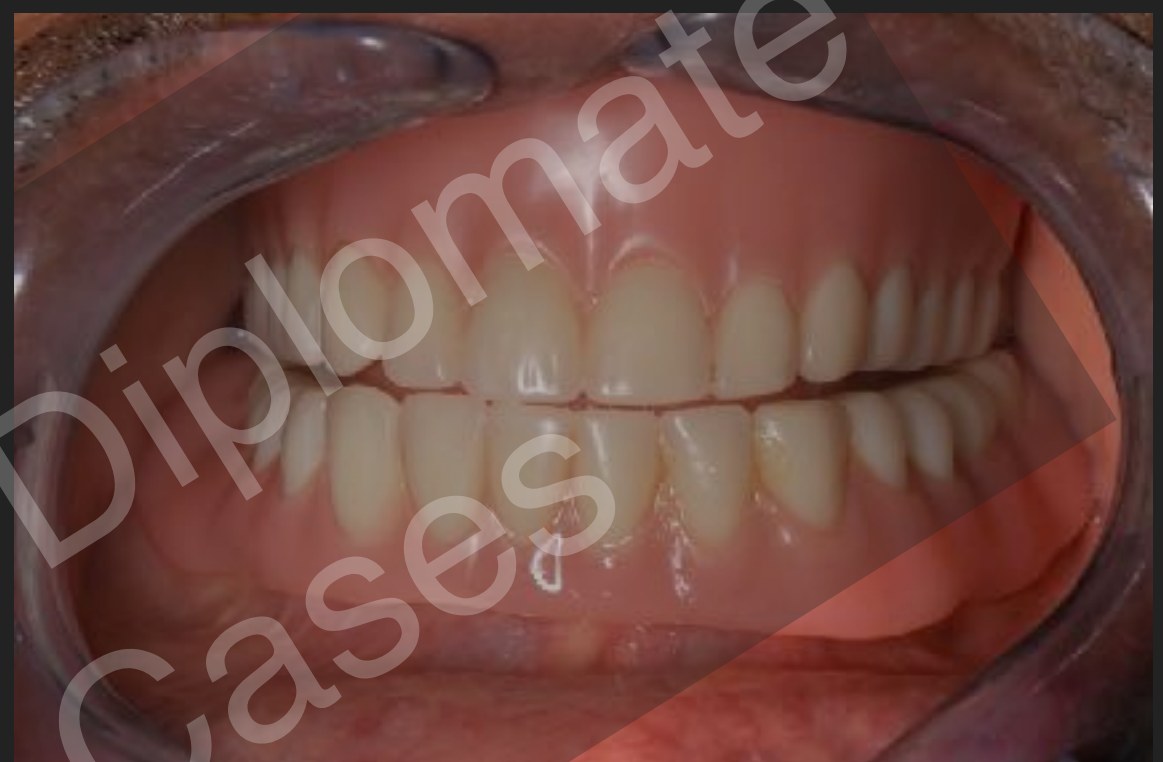- ▶ Name Of Patient: Mr XYZ
- ▶ Diagnosis: Total Edentulism
- ▶ Treatment Plan: Full arch removable implant overdenture with 2 implants
- ▶ Procedures: Two endosseous implants placed one each in Mandibular Left & Right Lateral incisor regions. with Restored Mandibular complete denture assisted by 2 implants splinted by Hader Bar & Maxillary complete denture
- ▶ Implants and augmentation Materials used (please provide details): Biohorizons Internal laser lock 4.0X15 mm implants for both locations. No augmentation was performed

CASE NO 1: Photographs- 1-4 **Post op** (Min 1 Year)

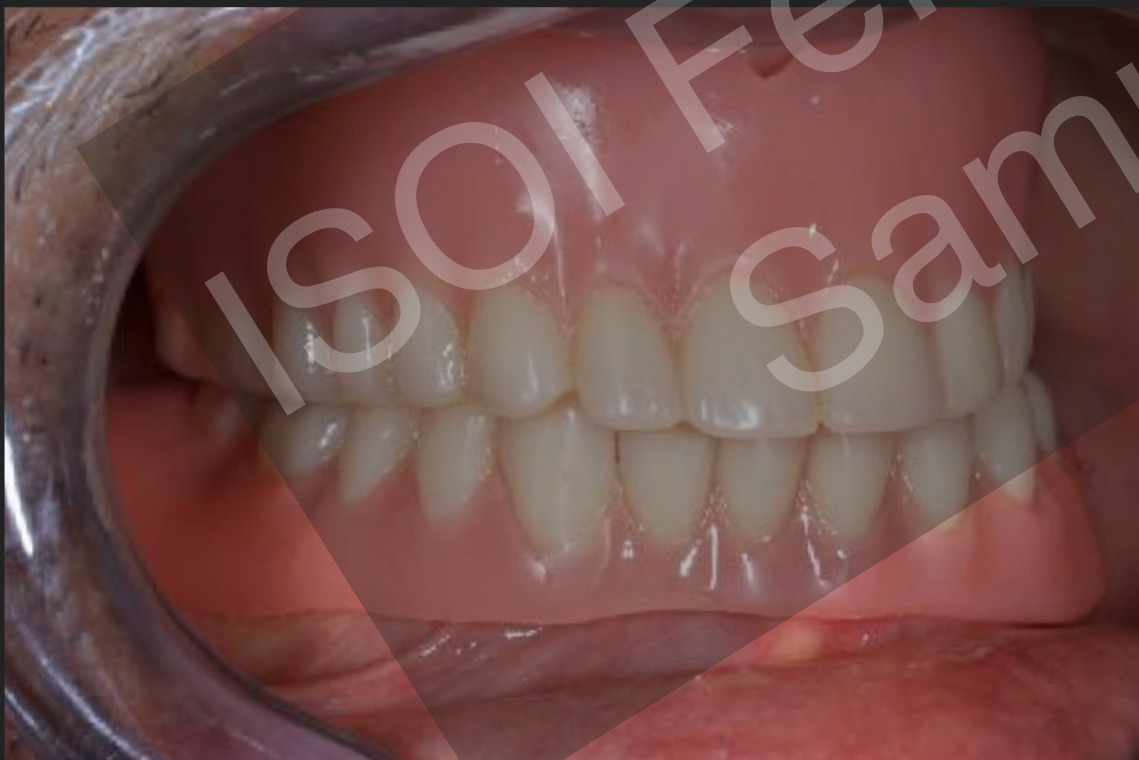View 1- Front: Centric Occlusion dd.mm.yyyy



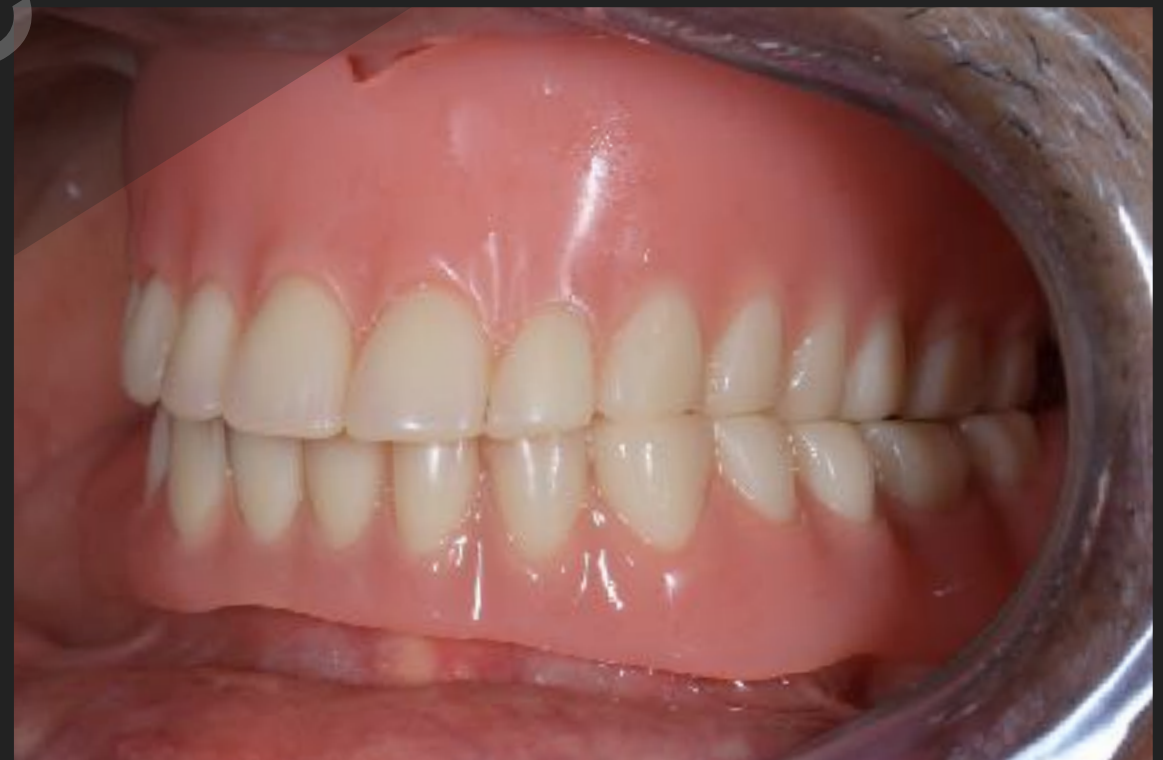View 2- Front: Protrusive dd.mm.yyyy



View 3- Right: Centric Occlusion dd.mm.yyyy

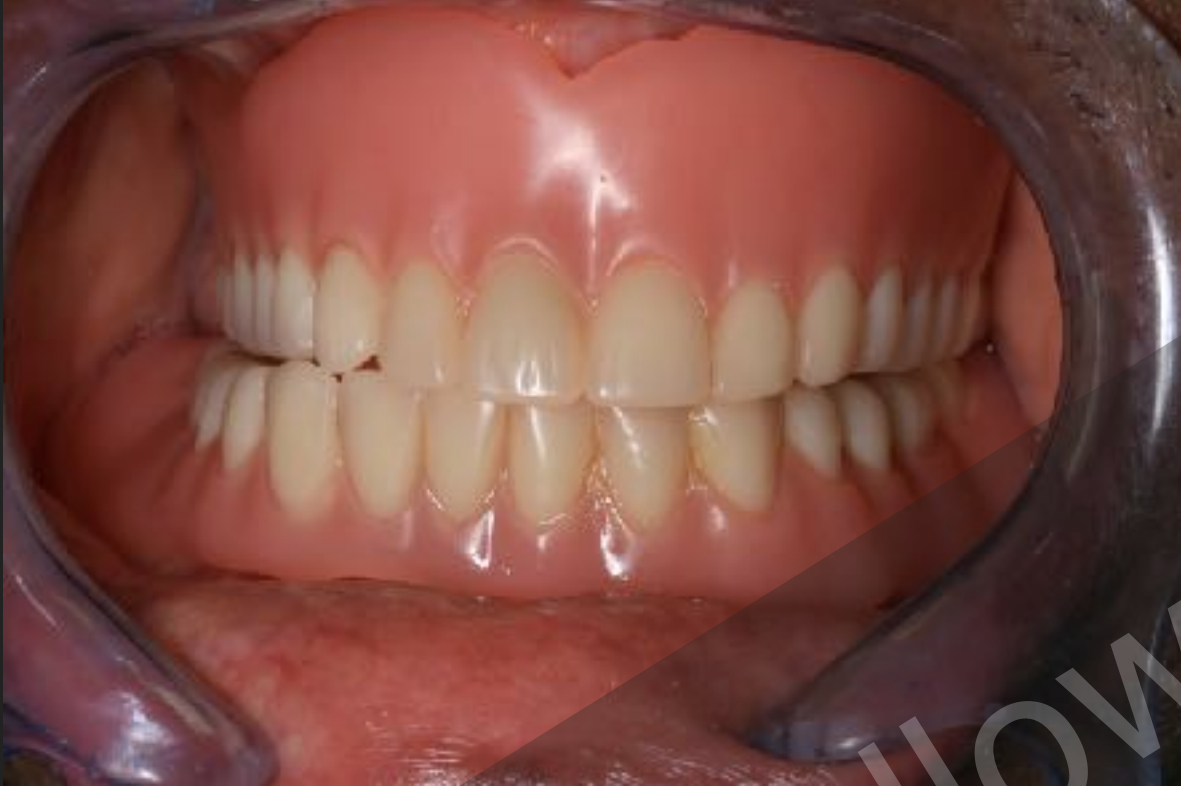

View 4- Left: Centric Occlusion dd.mm.yyyy

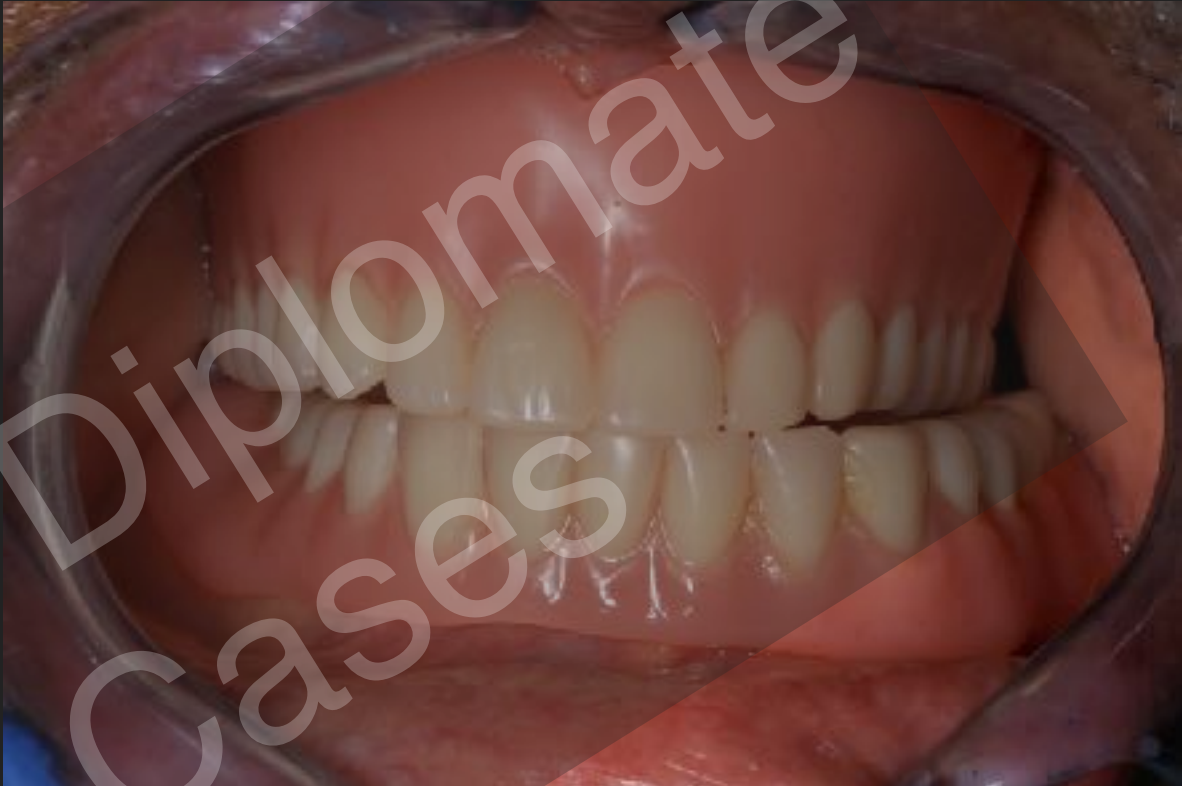

CASE NO 1: Photographs- 5-8 **Post op** (Min 1 Year)

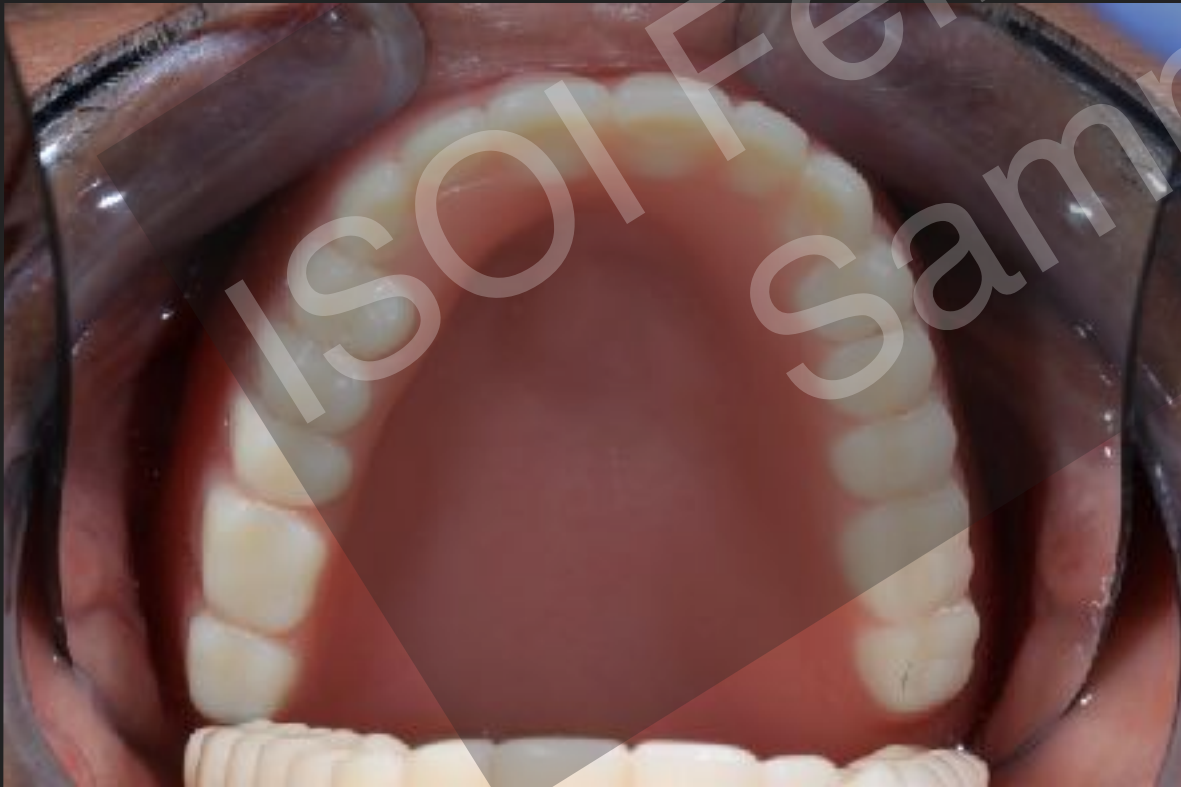View 5- Front: Right Excursive dd.mm.yyyy



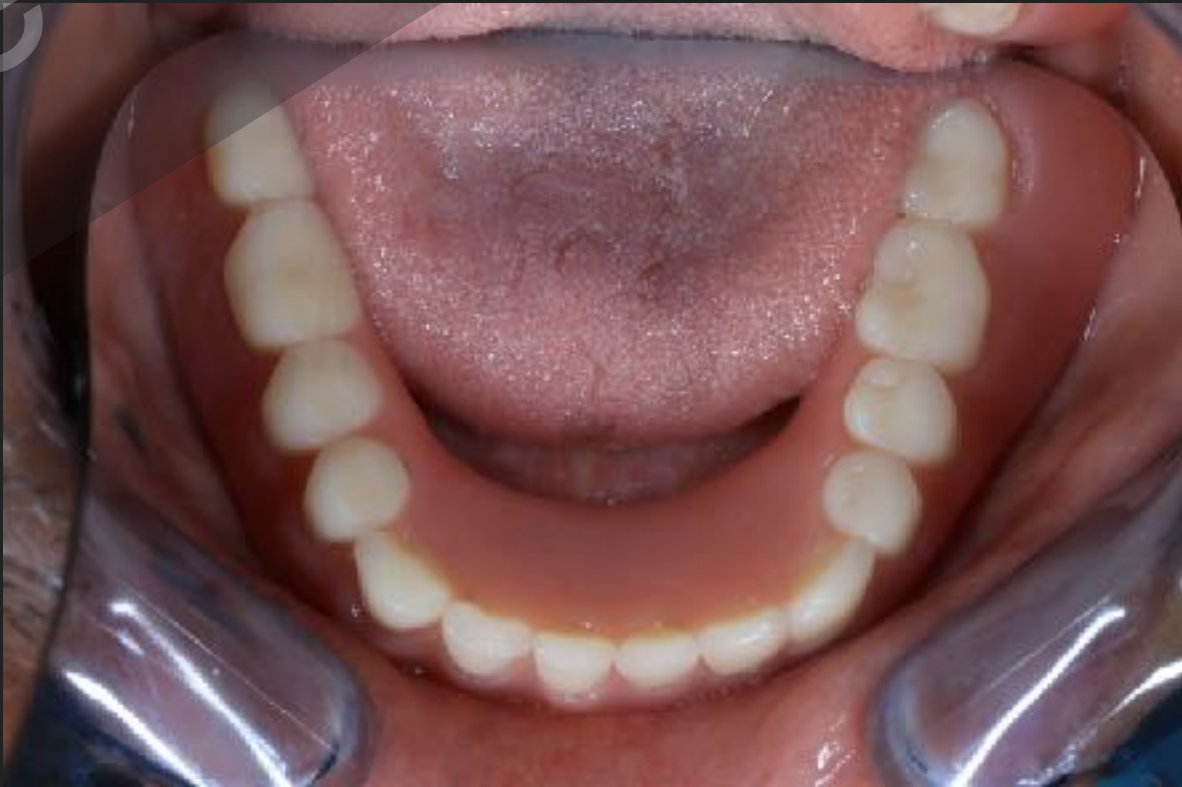View 6- Front: Left Excursive dd.mm.yyyy



View 7- Maxillary Occlusal dd.mm.yyyy

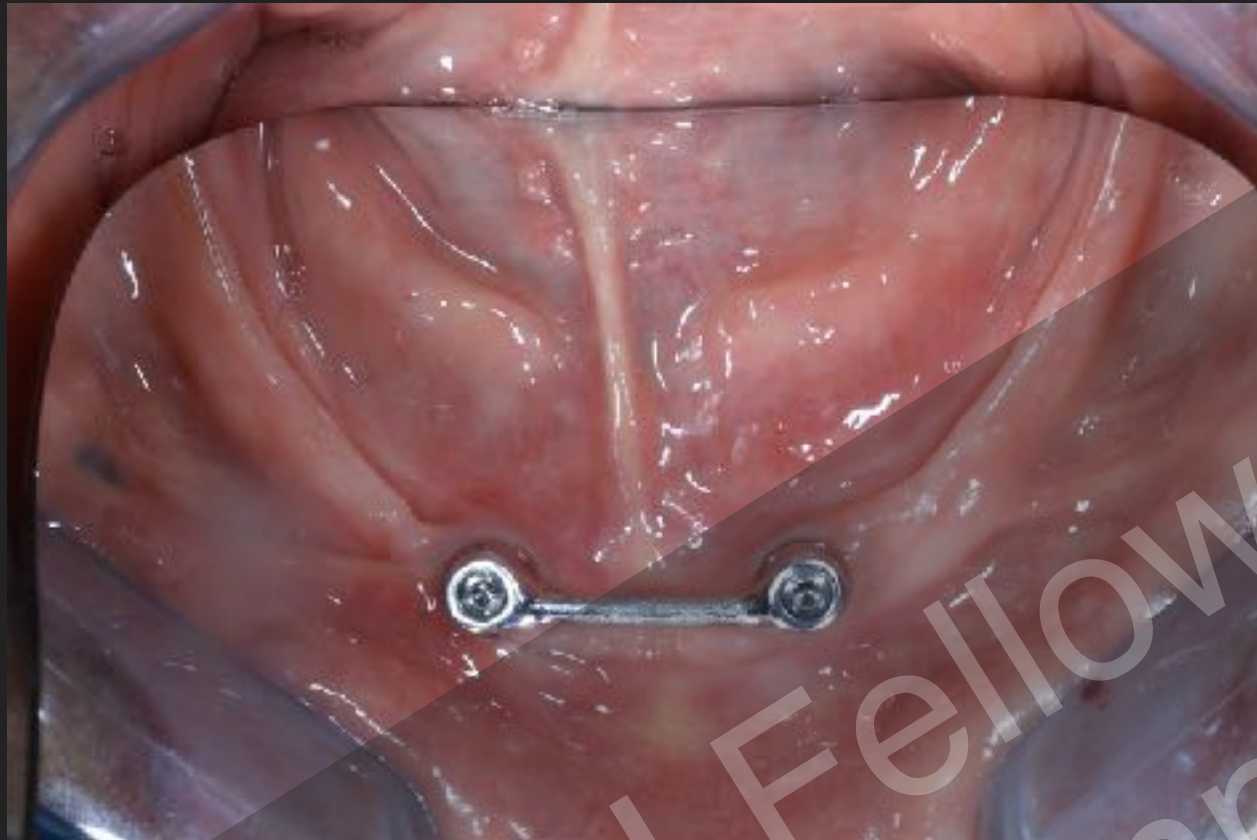

View 8- Mandibular Occlusal dd.mm.yyyy

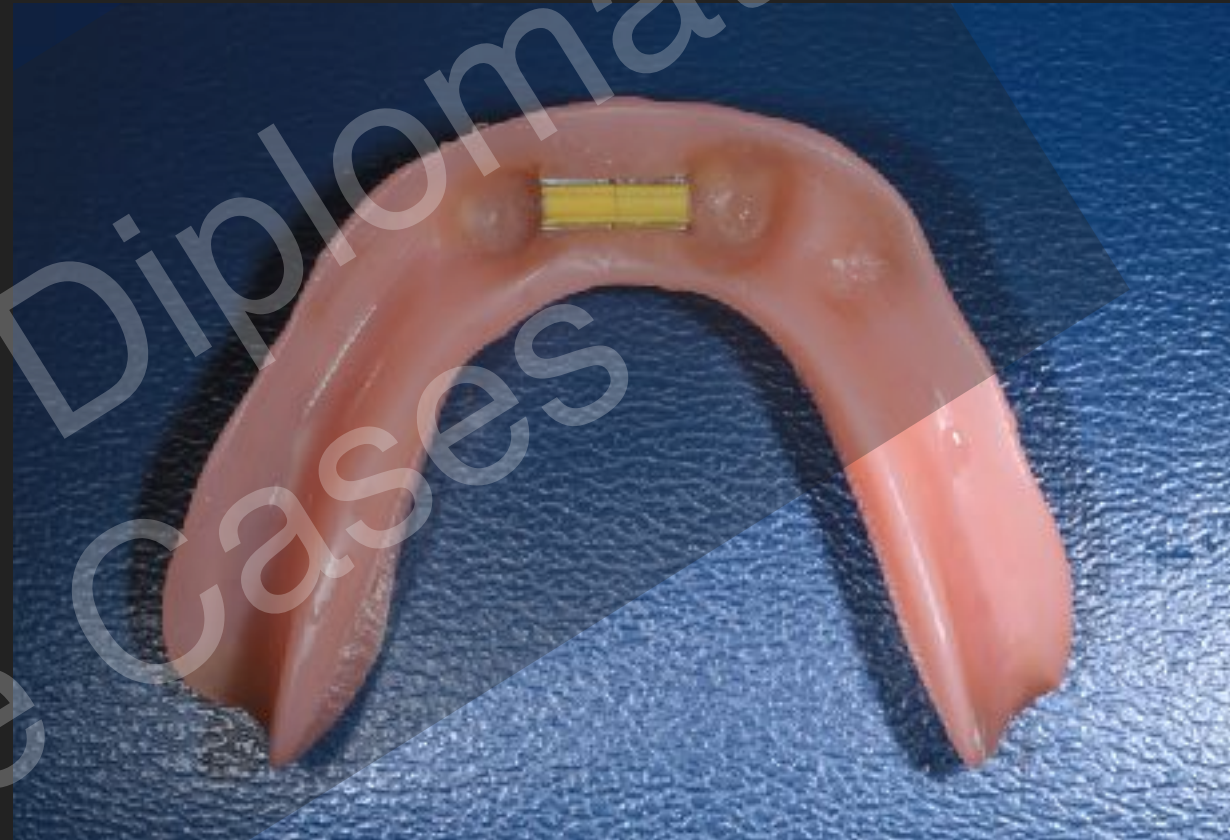

CASE NO 1: Photographs- 5-8 **Post op** (Min 1 Year)

View 5-Occlusal View of the intraoral attachment- Hader bar dd.mm.yyyy



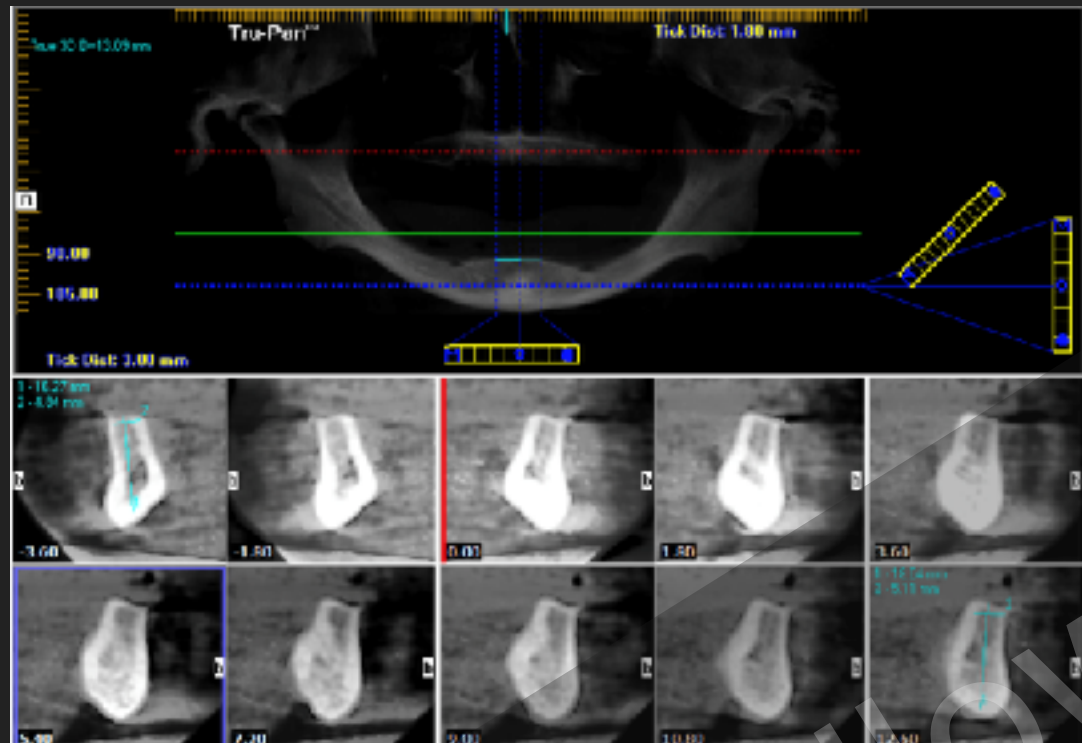
View 6- View of the tissue surface of the complete denture dd.mm.yyyy



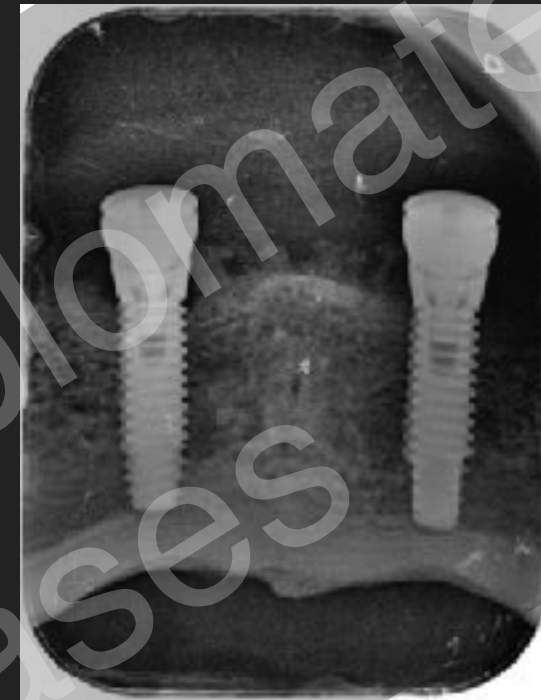ISOI Fellow - Diplomat
Sample Cases

CASE NO 1: Radiographs 1-4 **Post op** (Min 1 Year)

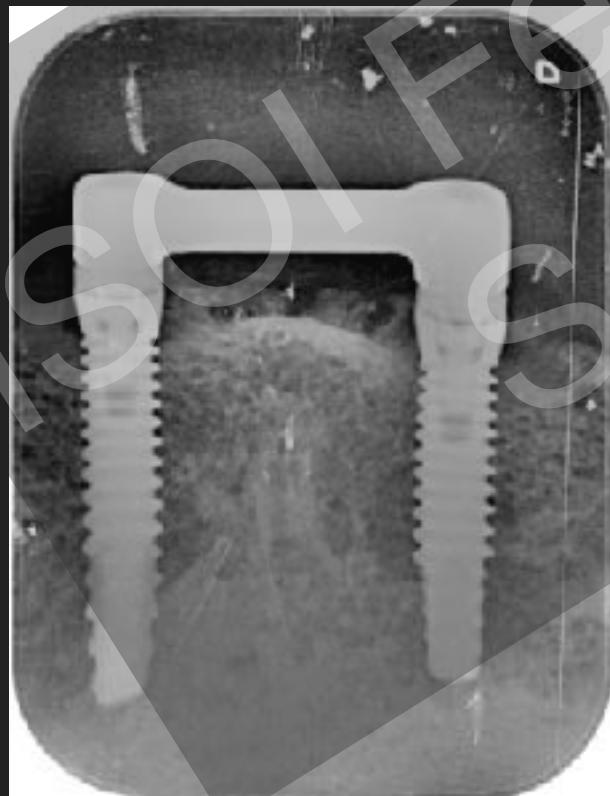
View 1- Pre surgical dd.mm.yyyy



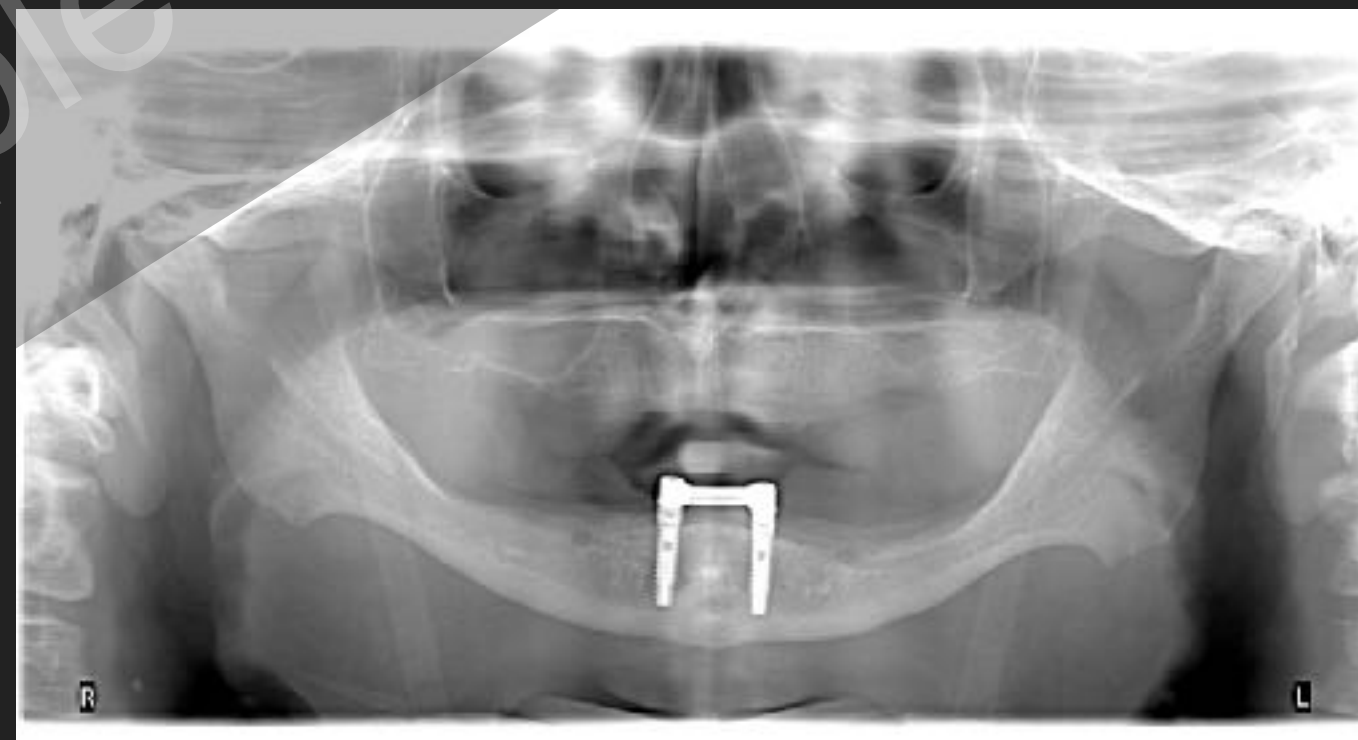View 2 - Immediate Post Surgical dd.mm.yyyy



View 3- Immediate Post Prosthetics dd.mm.yyyy

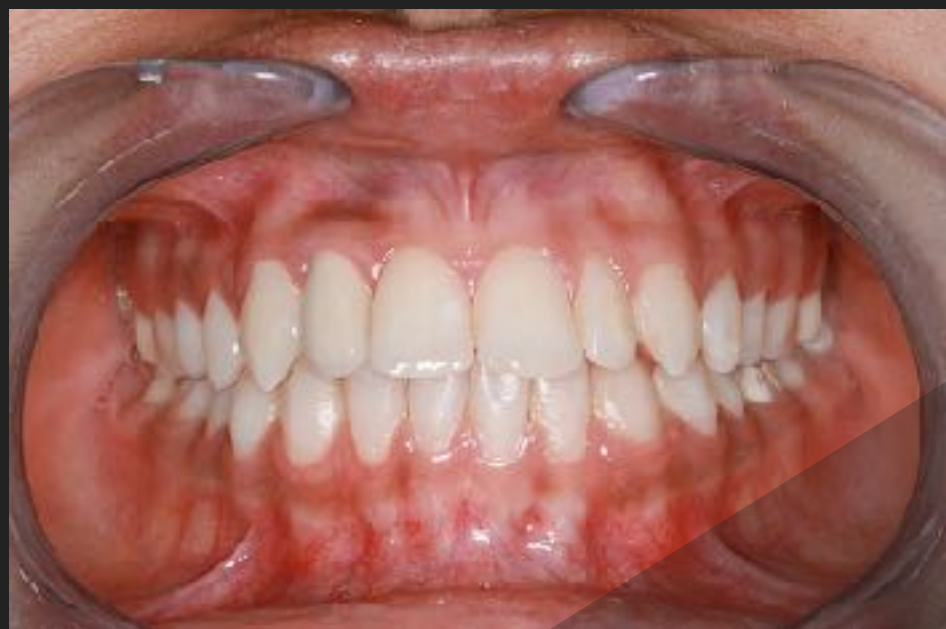

View 4 - 1 Year Followup dd.mm.yyyy

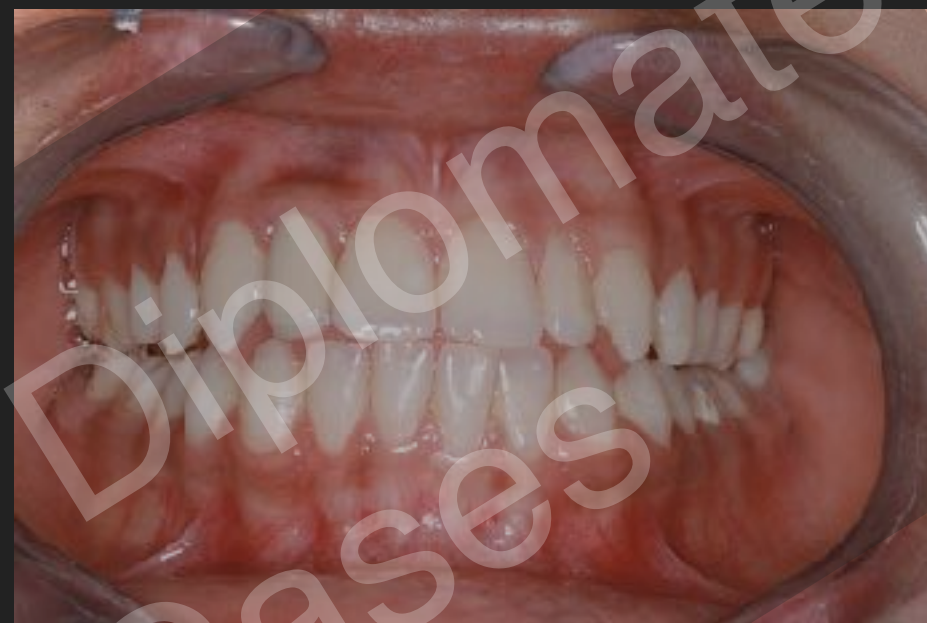

CASE NO 2: Photographs- 1-4 **Post op** (Min 1 Year)

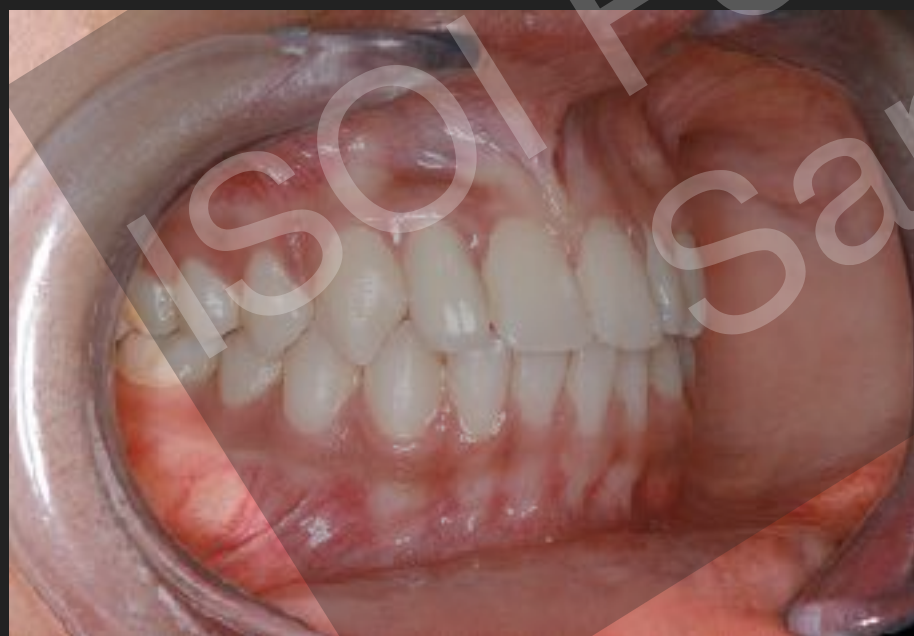View 1- Front: Centric Occlusion dd.mm.yyyy



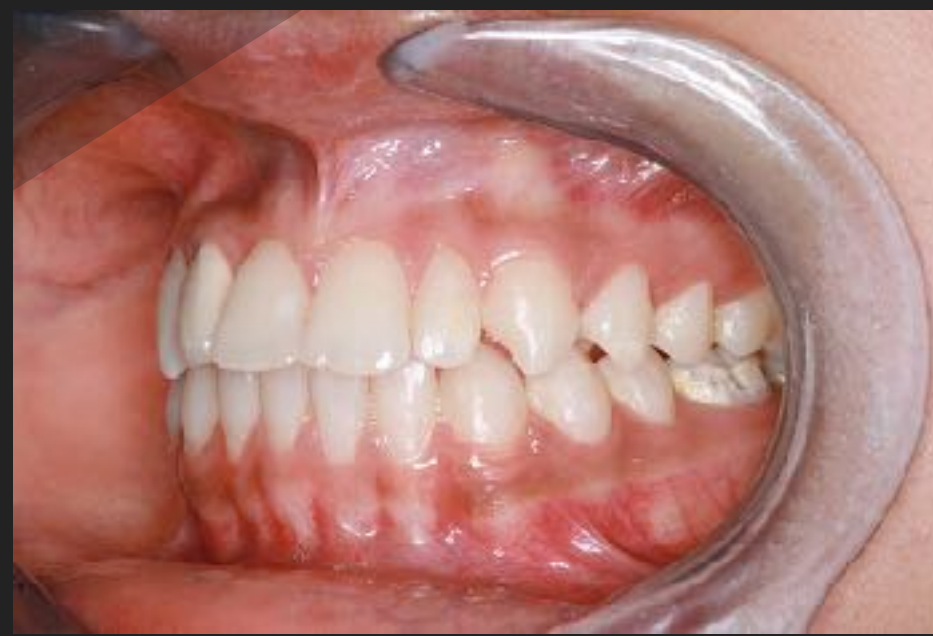View 2- Front: Protrusive dd.mm.yyyy



View 3- Right: Centric Occlusion dd.mm.yyyy

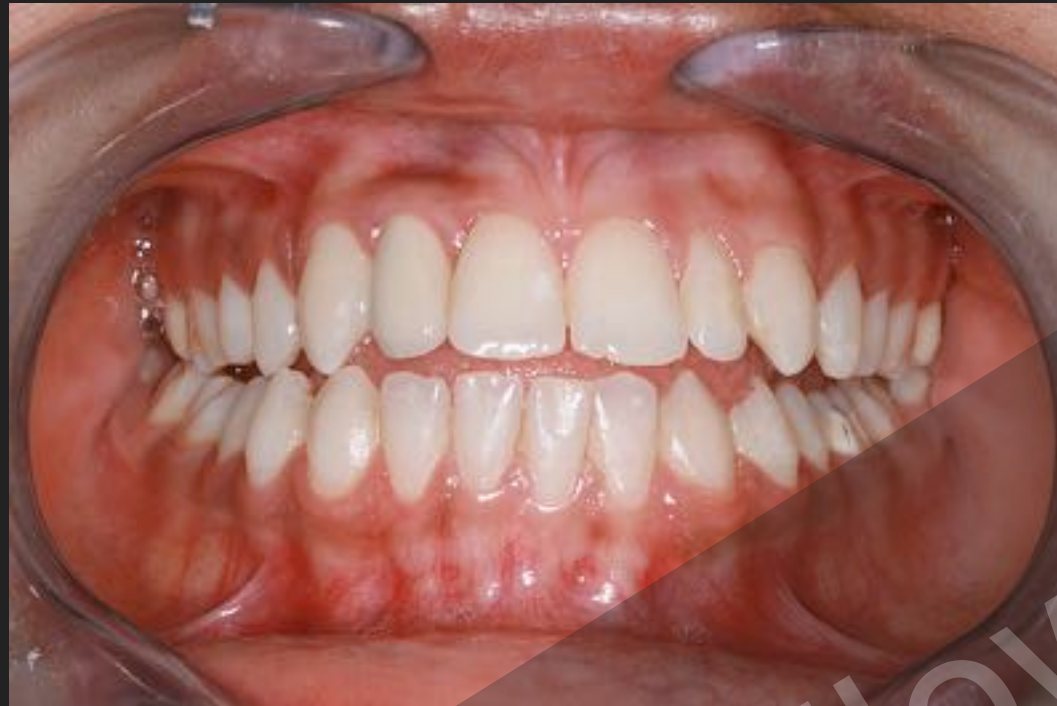

View 4- Left: Centric Occlusion dd.mm.yyyy

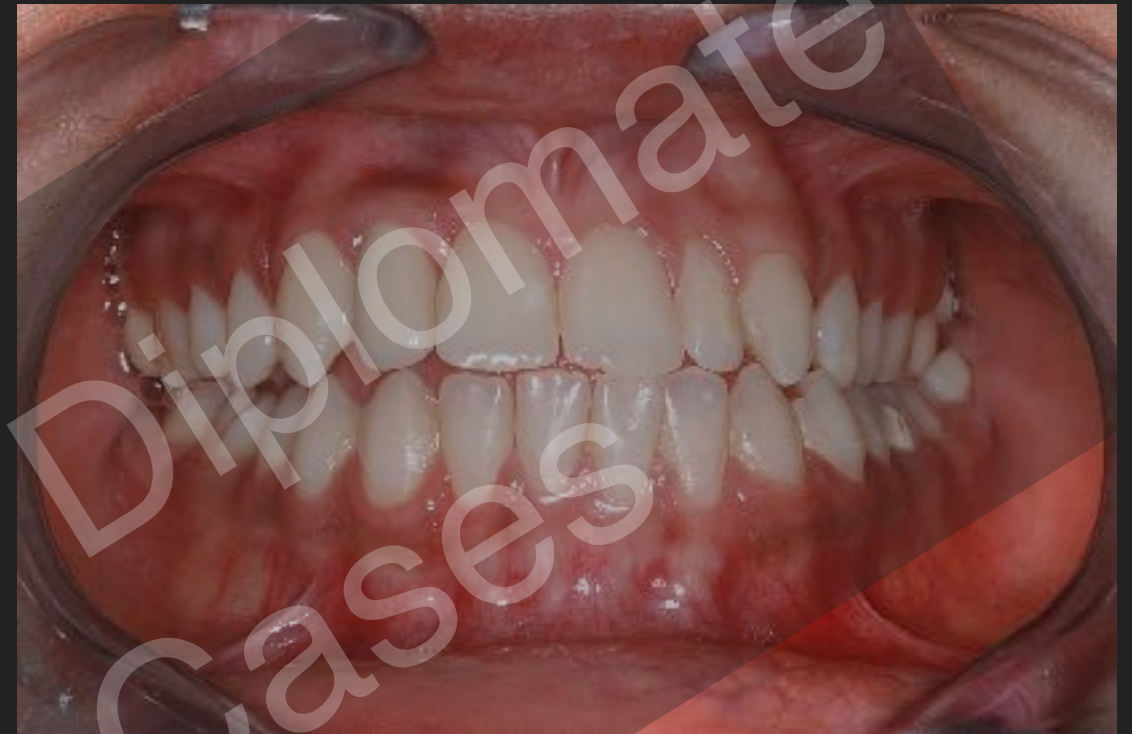

CASE NO 2: Photographs- 5-8 **Post op** (Min 1 Year)

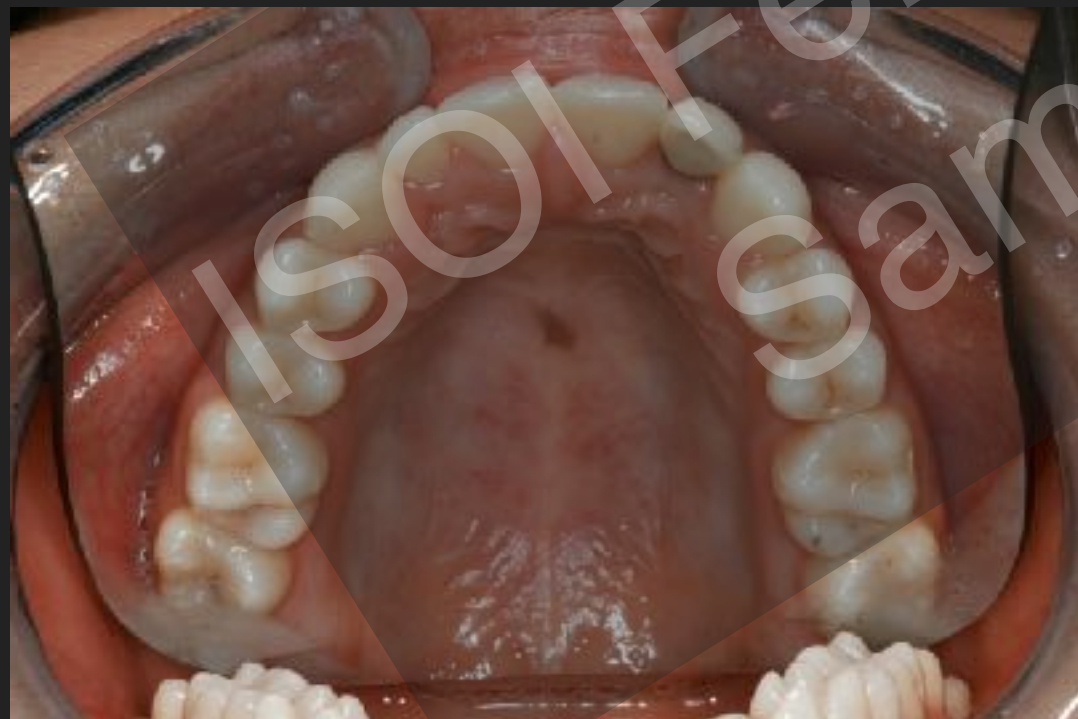View 5- Front: Right Excursive dd.mm.yyyy



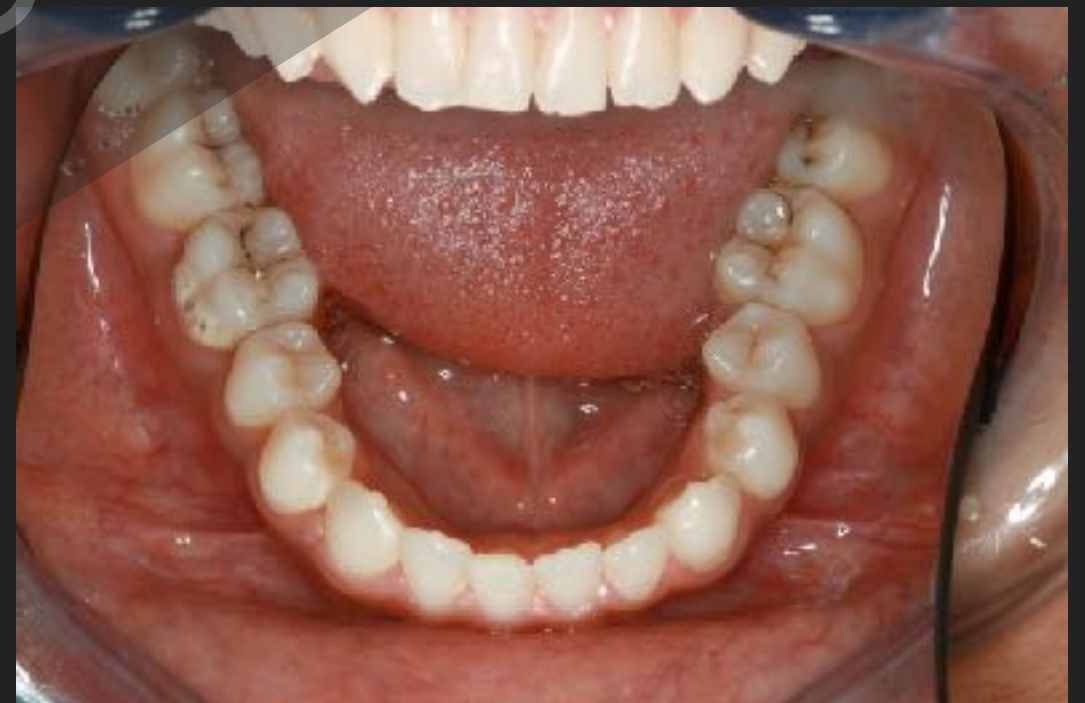View 6- Front: Left Excursive dd.mm.yyyy



View 7- Maxillary Occlusal dd.mm.yyyy

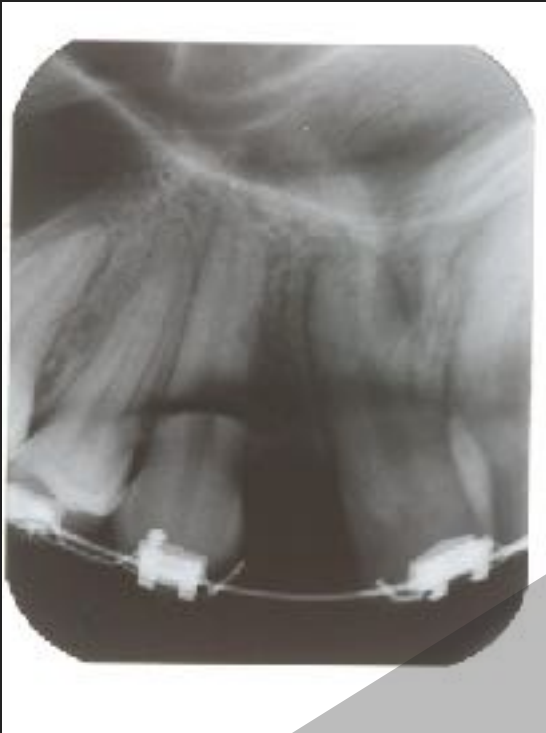

View 8- Mandibular Occlusal dd.mm.yyyy

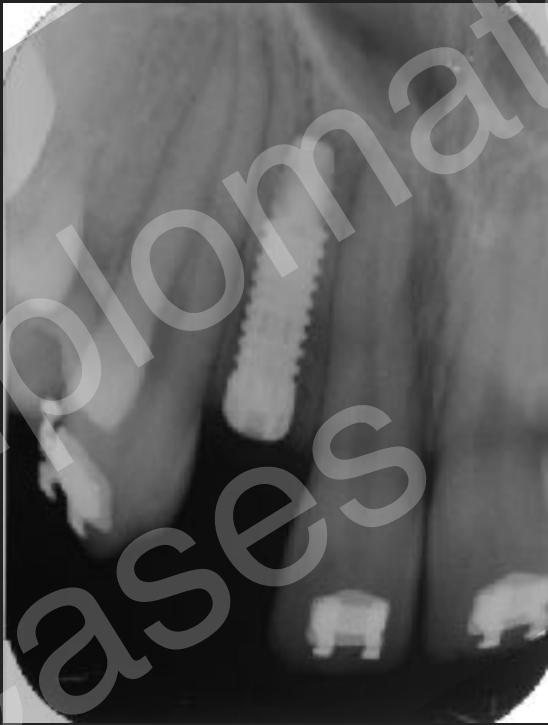

CASE NO 2: Radiographs 1-4 **Post op** (Min 1 Year)

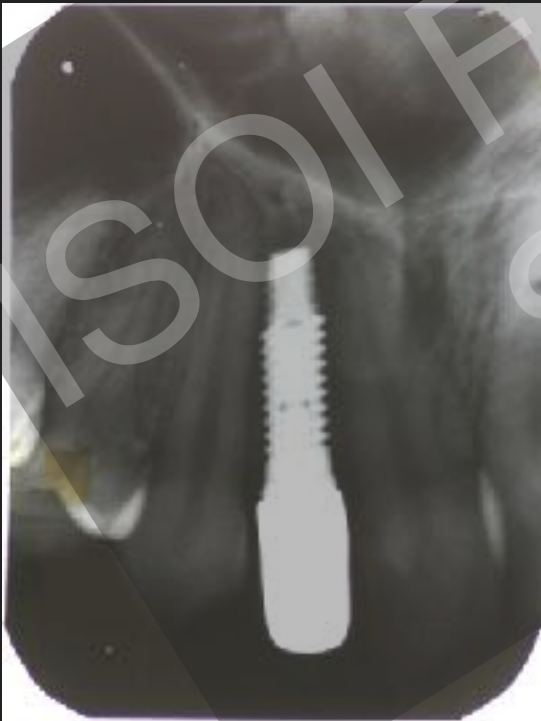View 1- Pre surgical dd.mm.yyyy



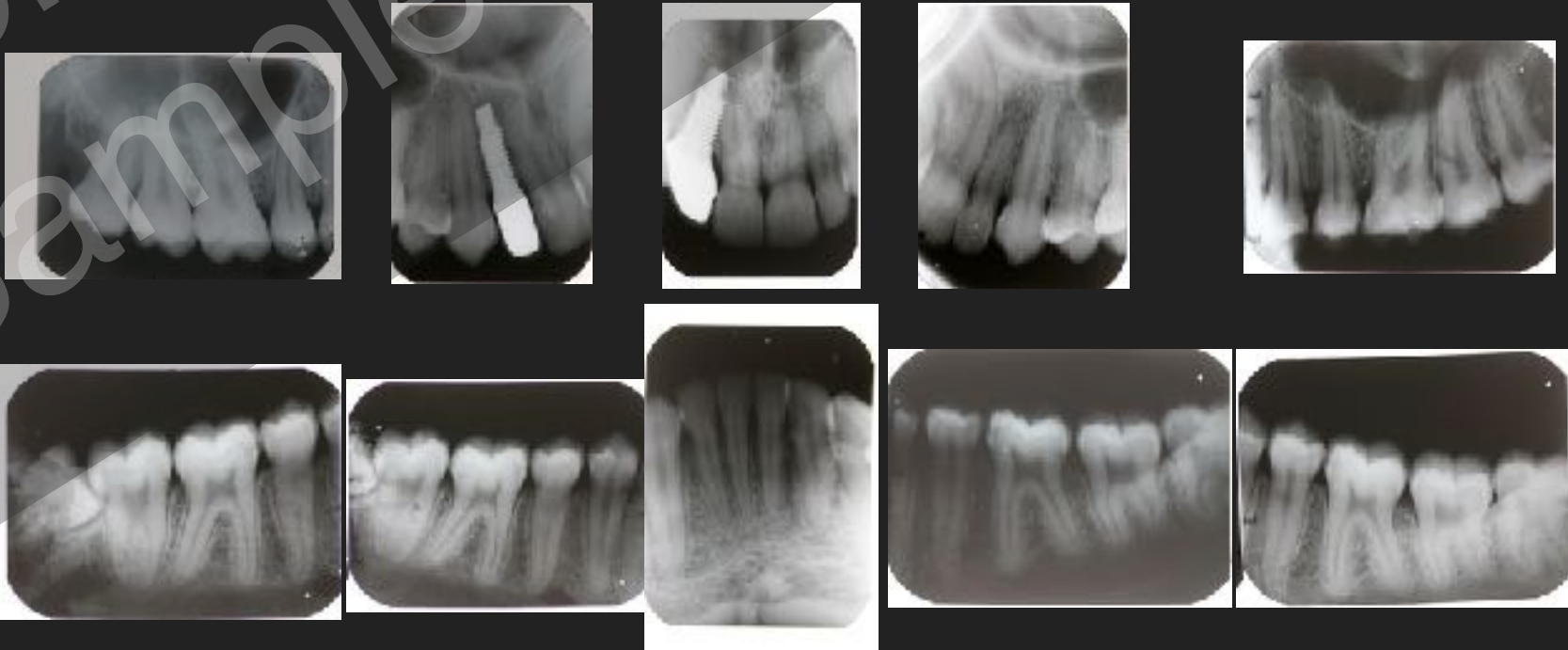
View 2 - Immediate Post Surgical dd.mm.yyyy



View 3- Immediate Post Prosthetics dd.mm.yyyy

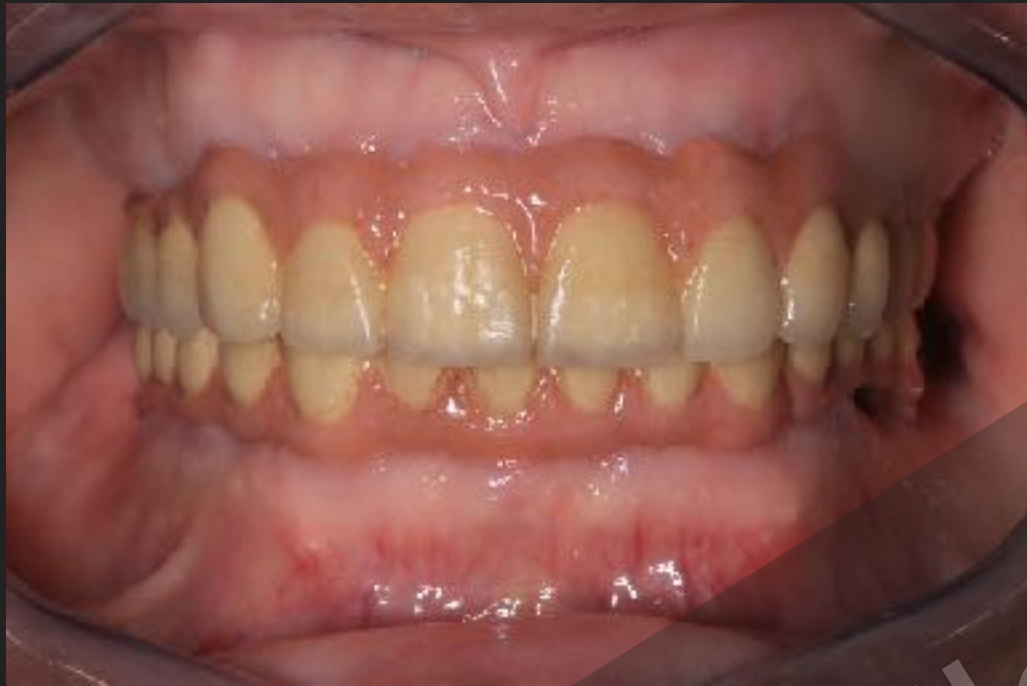

View 4 - 1 Year Followup dd.mm.yyyy

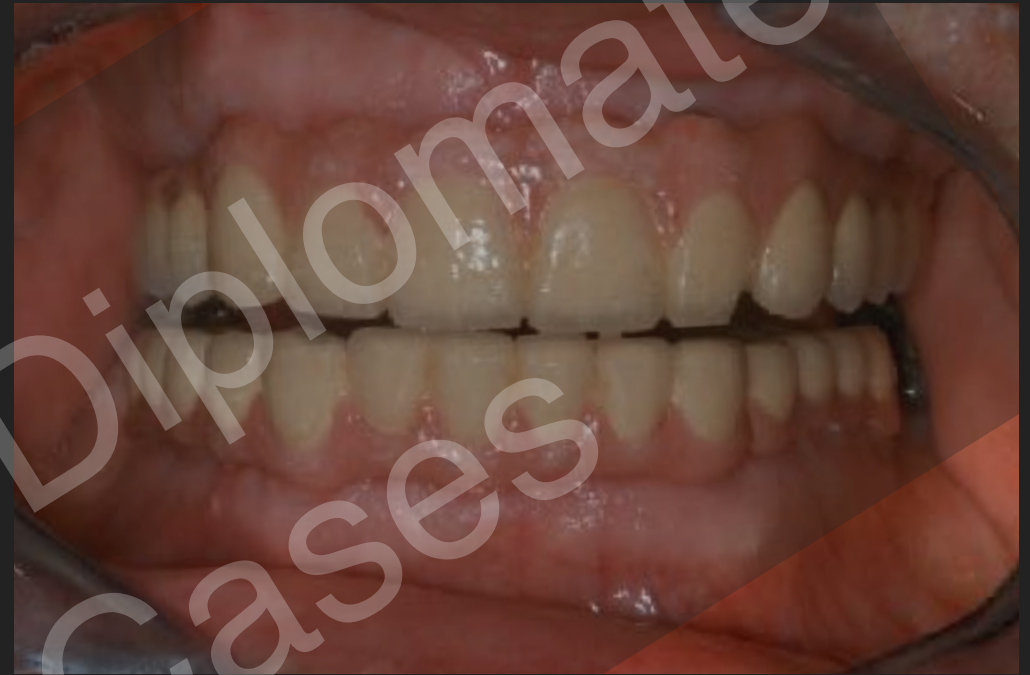

CASE NO 3: Photographs- 1-4 **Post op** (Min 1 Year)

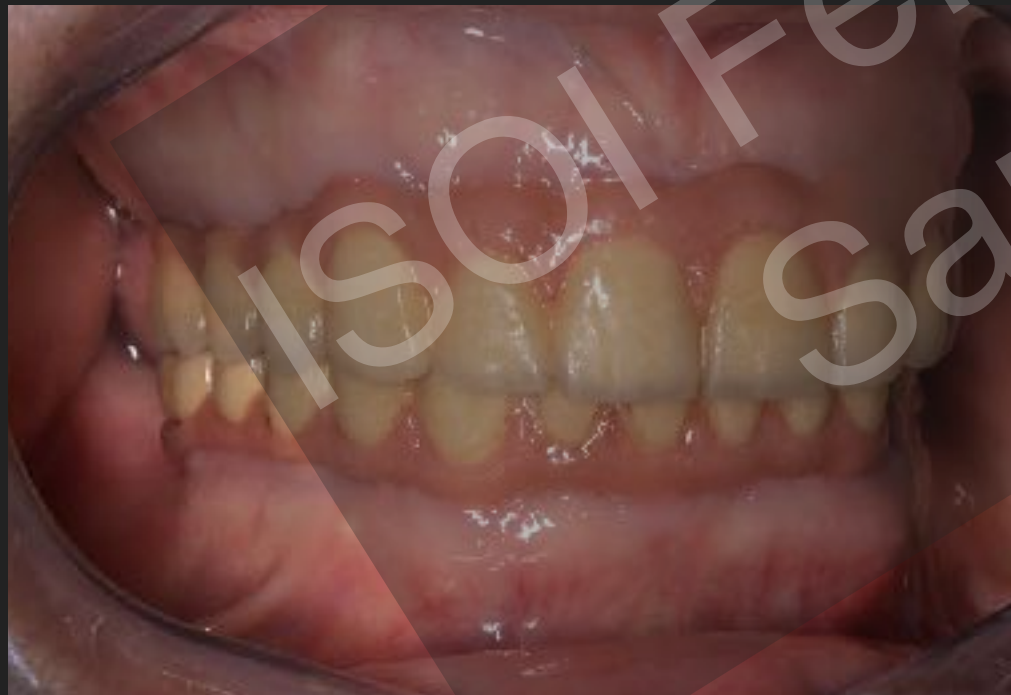View 1- Front: Centric Occlusion dd.mm.yyyy



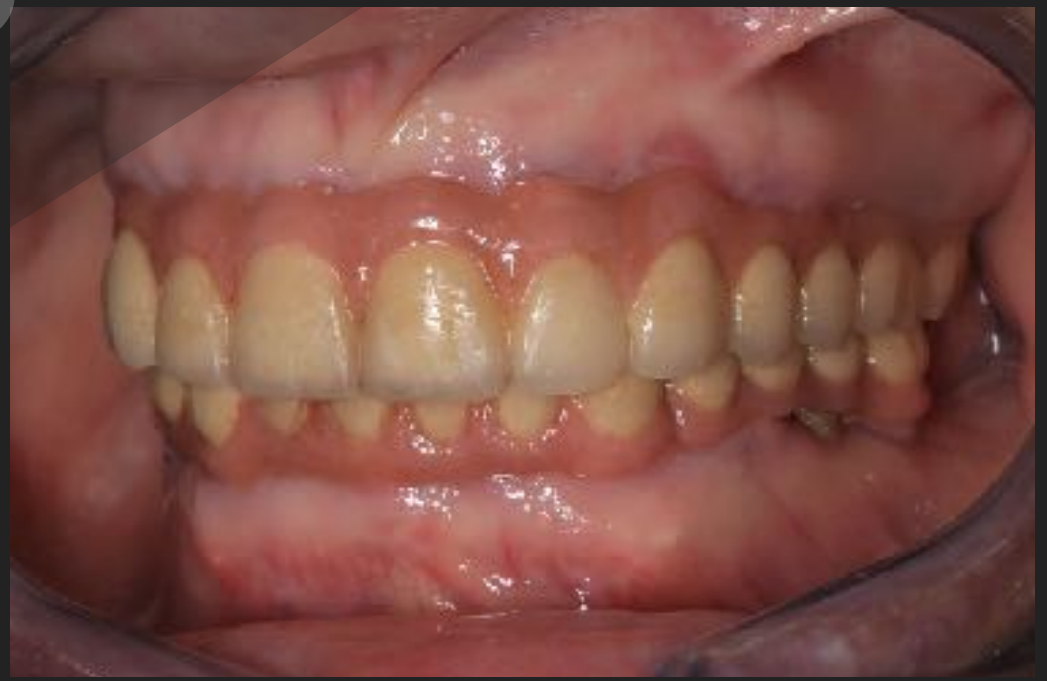View 2- Front: Protrusive dd.mm.yyyy



View 3- Right: Centric Occlusion dd.mm.yyyy

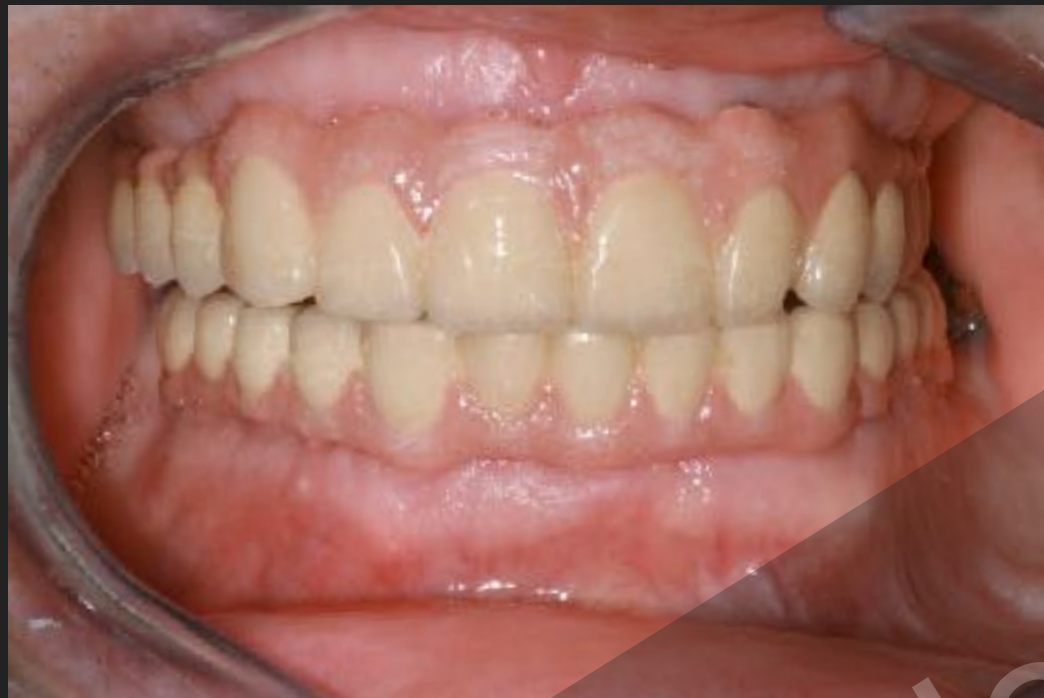

View 4- Left: Centric Occlusion dd.mm.yyyy

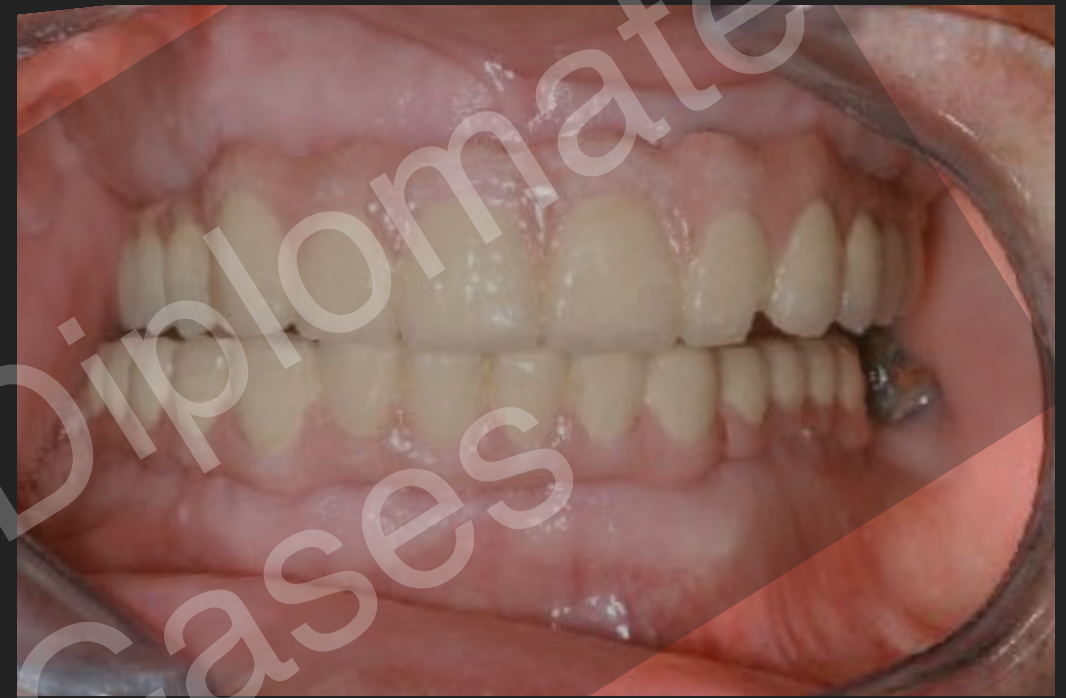

CASE NO 3: Photographs- 5-8 **Post op** (Min 1 Year)

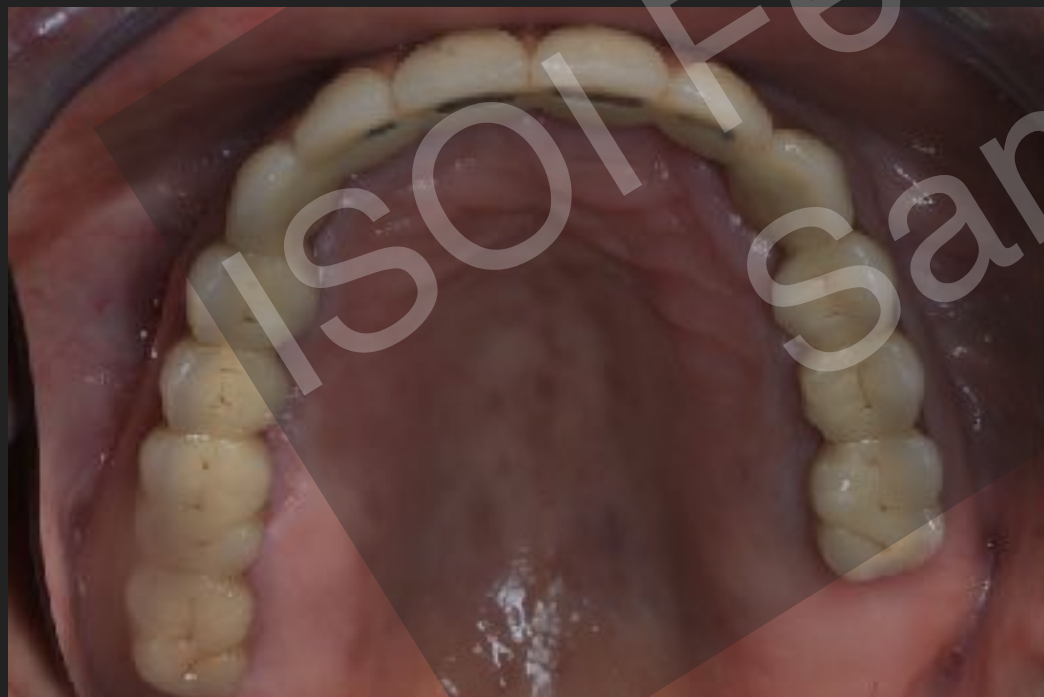View 5- Front: Right Excursive dd.mm.yyyy



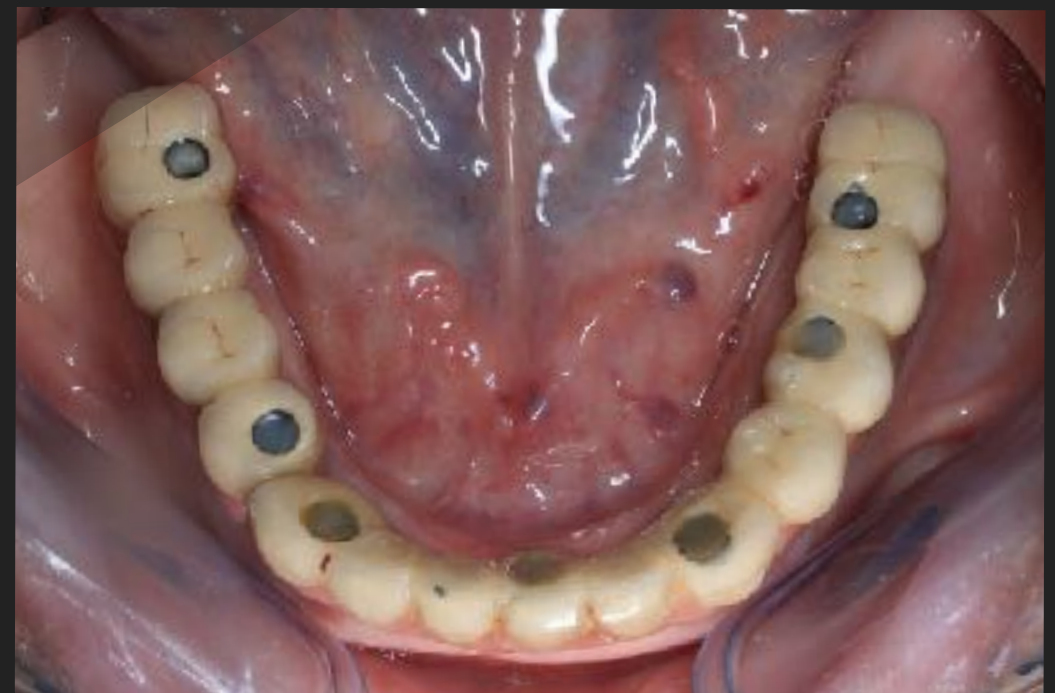View 6- Front: Left Excursive dd.mm.yyyy



View 4- Maxillary Occlusal dd.mm.yyyy

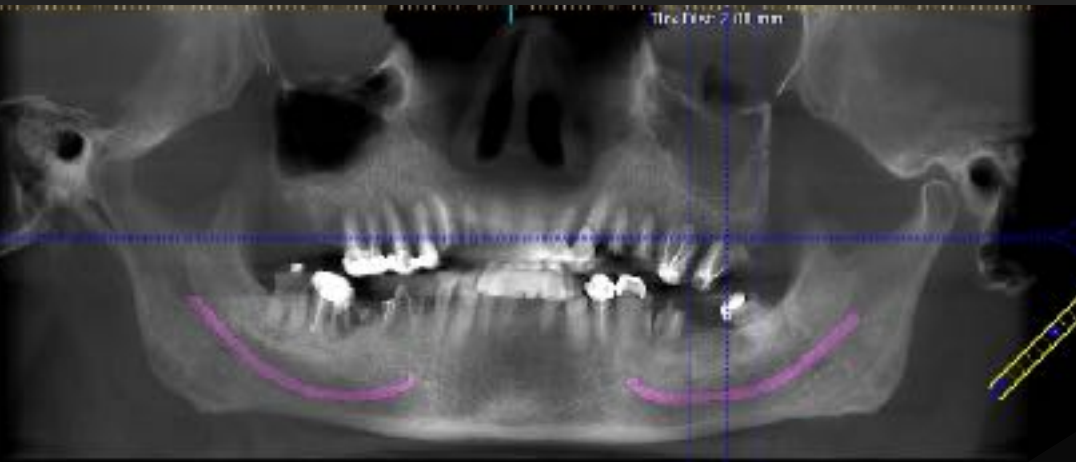


View 5- Mandibular Occlusal dd.mm.yyyy

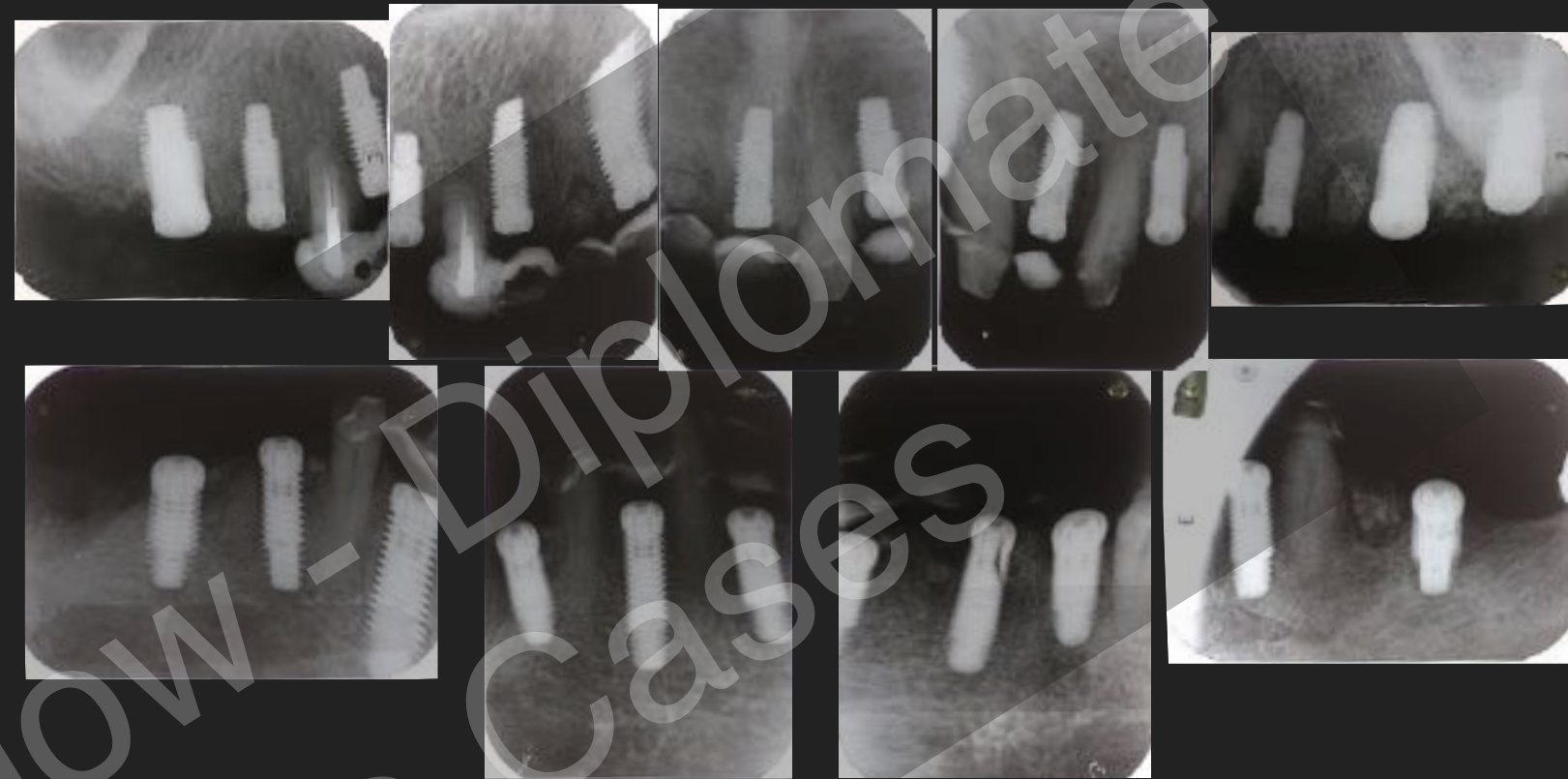

CASE NO 3: Radiographs 1-4 **Post op** (Min 1 Year)

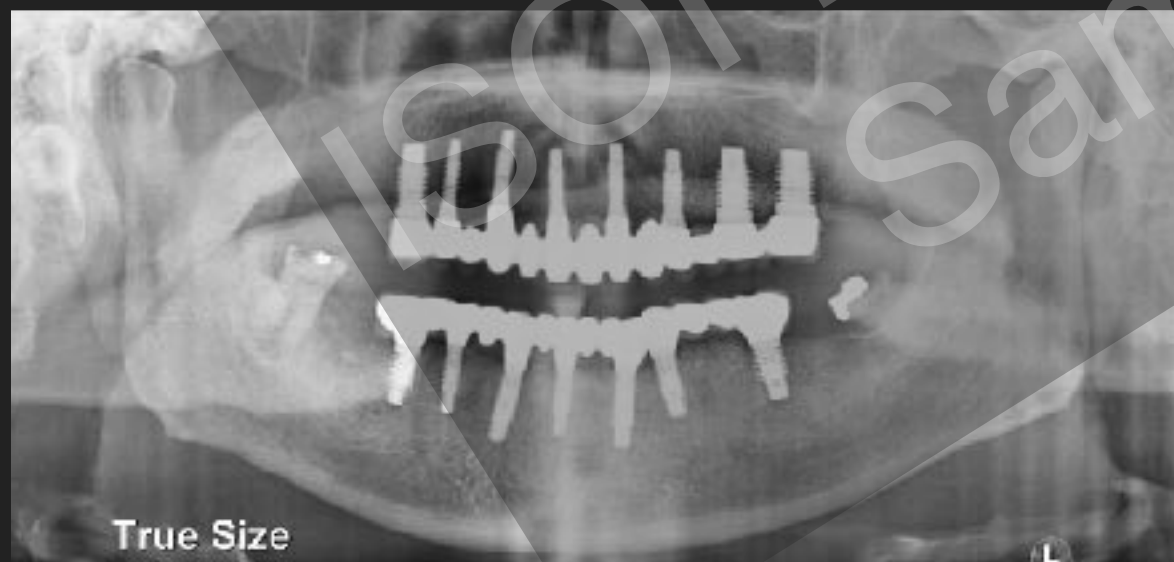View 1- Pre surgical dd.mm.yyyy



View 2 - Immediate Post Surgical dd.mm.yyyy



View 3: immediate post prosthetics



View 4: 1 year follow up

