

DISTRIBUTION AND HISTOLOGICAL STRUCTURE OF PEYER'S PATCHES IN THE LARGE INTESTINE OF THREE-MONTH-OLD CALVES

Saw Po Po, A.B.Z Zuki, M. Zamri-Saad, A. Rahman-Omar and A.W. Effendy

¹Faculty of Veterinary Medicine, Universiti Putra Malaysia,
43400 UPM Serdang, Selangor, Malaysia

²Kolej Universiti Sains dan Teknologi Malaysia (KUSTEM), Menggabang Telipot,
Kuala Terengganu, Terengganu, Malaysia

SUMMARY

Distribution and histological structure of aggregated lymphoid tissues (Peyer's patches) of the large intestine were evaluated in three-month-old calves. The first patch was situated in the ileocaecal entrance, second patch in the proximal colon and third in the rectum. The length of Peyer's patches in the proximal colon varied from 4 to 8 cm. Macroscopically, the patches at ileocaecal entrance and proximal colon were clearly seen, whereas the rectal patch was inconspicuous. Histologically, the Peyer's patches of the large intestine consisted of lymphoglandular complex and lamina propria nodules. The lymphoglandular complex was located within the submucosa that contains epithelial diverticula, which extends from muscularis mucosae. The lamina propria nodules were located in the lamina propria. The propria nodules were surrounded by wide crypts, lined by distinct follicle-associated epithelium and lacked goblet cells. The lymphoglandular complexes were covered with distinct follicle-associated epithelium with numerous intraepithelial lymphocytes and lacked goblet cells. Intraepithelial lymphocytes were distributed in the epithelial layer of the large intestine and formed a unique lymphocyte population. Some Peyer's patches of the large intestine were similar to that of jejunal Peyer's patches as they contained broad follicles, distinct corona areas and wide interfollicular areas.

Keywords: Large intestine, Peyer's patches, calves

INTRODUCTION

Mucosa associated lymphatic tissue of bovine large intestine is a major pathway for entry of infectious agents into intestinal tract (Owen, 1983) and play a significant role in controlling the local microbial populations immunologically (Gebert and Bartels, 1995). Colonic lymphoid patches in the proximal colon are the site of damage by bovine viral diarrhoea and Cryptosporidium spp (Pohlenz *et al.*, 1986). Macroscopically, there are 3 locations of lymphoid aggregates in the large intestine in ruminants (Carlens, 1928) such as proximal colon close to the ileocaecal opening, ascending colon at the beginning of the spiral colon and in the rectum close to the recto-anal junction. Carlens (1928) found the aggregated follicles in ascending colon, proximal to the patch at the beginning of the spiral colon and solitary follicles in the first part of the spiral colon of lambs. In domestic cows, gut associated lymphatic tissues are present as solitary lymphoid follicles throughout the large intestine and are situated at ileocaecal entrance and in the proximal colon (Liebler, 1986). Histologically, there are two different types of lymphoid follicles such as propria nodules with lymphoid follicles and lymphoglandular complex with lymphoid follicles (Habel, 1960) and (Liebler *et al.*, 1988). Propria lymphoid nodules have lymphoid follicles predominantly in the lamina propria and are covered by follicle associated epithelium

(FAE). Lymphoglandular complexes are characterized by lymphoid follicles in the tunica submucosa and epithelial diverticulae that extend through the muscularis mucosae and branch into the lymphoid tissue. It has also been reported that the nodules are extremely sensitive to steroid treatment (Perry and Sharp, 1988). This response was also seen in the bursa of Fabricius. In addition, the proximal colonic lymphoid tissues contain a high number of relatively immature B cells and may be a primary site of generation and the majority of lymphoid cells in these nodules rarely show well-developed germinal centers (Perry and Sharp, 1988).

Thus, the study was conducted with the aim of describing the macroscopic and light microscopic features of the large intestine of three-month old calves. In addition, the amount of intraepithelial lymphocytes of crypts of large intestine were counted and compared.

MATERIALS AND METHODS

Animals

Three calves of local breed and aged 3 months were used in this study. The calves were supplied by the University Research Park, Universiti Putra Malaysia. The calves were left free grazing with their mothers in the field. The calves were healthy; physical examination on the calves did not reveal any abnormal findings.

Macroscopic examination

Upon slaughtering the calves, the large intestine was taken out and washed with phosphate buffer saline solution (pH 7.3) to remove all contents. The large intestine was ligated at seven different sites: the ileocaecal junction, proximal end, middle and distal end of colon, proximal end, middle and distal end of rectum. The intestinal lumen was then inserted with 10% neutral buffered formalin. After 30 min, the ligations were opened and the intestine was cut and opened along the mesenteric attachment site. The mucosal surface was rinsed gently with cold water for 2 h and then transferred into freshly prepared fixative solutions. The number and size of Peyer's patches were counted, measured and recorded. The size of Peyer's patches was calculated as the length multiplied by its width.

Light microscopic examination

For microscopic examination, caecum, three sites (proximal, middle and distal parts) of each colon and rectum containing lymphoid follicles were sampled and fixed in 10% neutral buffered formalin solution (pH 7.3), embedded in paraffin, sectioned at 4 μm and stained with Haematoxylin and Eosin. At least 24 longitudinally sectioned follicles per sample were counted at a magnification of 100x using the division of an ocular grid (100 rectangles, 1mm² total areas). The size of the follicles with their length and width were measured using image analyzer (Synoptic Inc., UK) and were recorded. The slides were examined under light microscope with 400x magnification using the division of ocular grid to count intraepithelial lymphocytes (IELs). The IELs were counted in the portion of randomly selected crypts, which filled the field. A total of four fields from six crypts were examined and classified as subnuclear, nuclear and supranuclear according to their plane with relationship to the nucleus of adjacent absorptive cells. The IEL count was based on morphological appearance (i.e. cells located on the luminal side of the basement membrane, with high nuclear to cytoplasm ratio causing distortion of the columnar epithelial cells and with a halo of clear cytoplasm around the nucleus) (Sturgess *et al.*, 2001). The results are presented as mean \pm standard deviation per 50 epithelial cells.

Statistical analysis

Differences in number of lymphoid follicles, length, and width of lymphoid follicles and number of intraepithelial lymphocytes of crypts of different parts of large intestine were compared by one way analysis variance (one way ANOVA). The numerical results are expressed as mean \pm standard error of the mean and the statistical significant difference was evaluated at $P < 0.05$.

RESULTS

Macroscopic findings

The patches of the ileocaecal entrance, the proximal colon and rectum were all visible in the three-month-old calves. The patches found in the calves were generally small and indistinct. The first patch was found at the ileocaecal entrance and was situated at the center of the smooth rounded elevation. The patch was ovoid in structure and sometimes connected with the ileal Peyer's patches. The openings of the lymphoglandular complexes of mucosal surface were seen macroscopically (Figure 1). These openings were distributed uniformly throughout the ileocaecal orifice. Similar structures were present in the colon adjacent to the caecal opening. The second patch was located at the antimesenteric border of the proximal colon (Figure 2). The patch varied in length from 4 cm to 8 cm and in width from 2 cm to 2.5 cm respectively. Solitary lymphoid follicles were not seen in the proximal colon. At the end of the rectum, small triangular patches were evenly distributed around the circumference of the anus. The distribution and size of Peyer's patches in the large intestine are shown in Tables 1 and 2 respectively. The number and size of Peyer's patches were higher in the colon compared to the caecum and rectum.

Microscopic findings

Lymphoid tissues in large intestine were identified as two morphological types: the lamina propria nodules and lymphoglandular complex. They were located at the antimesenteric border. The lymphoglandular complex had a single, central invagination that passed through a gap in the muscularis mucosae to invade submucosal lymphoid tissue with branch diverticula that contain the elements of intestinal glands. Lymphoid follicles of lymphoglandular complex were located below the muscularis mucosae with crypts near the intestinal lumen extending down through the muscularis mucosae and branching into numerous smaller diverticula in the lymphoid tissue (Figure 3). Some lymphoglandular complex had single follicles and did not pass through the muscularis mucosae. The lymphoid follicles were rounded or oval shaped and were closely applied to the deep aspect of muscularis mucosae. Some follicles were longer with a distinct pale center and were mainly basophilic lymphocytes, lymphoblast and tangible macrophage. Some follicles were characterized by a wide interfollicular area and a distinct corona populated by numerous small lymphoid cells (Figure 4). These characteristics were similar to the jejunal Peyer's patches of the small intestine. Post capillary venules with many lymphocytes in their walls were observed with lymphatic often presenting large numbers of lymphocytes. Morphologically, the follicles showed markedly fewer germinal centers than typical Peyer's patches.

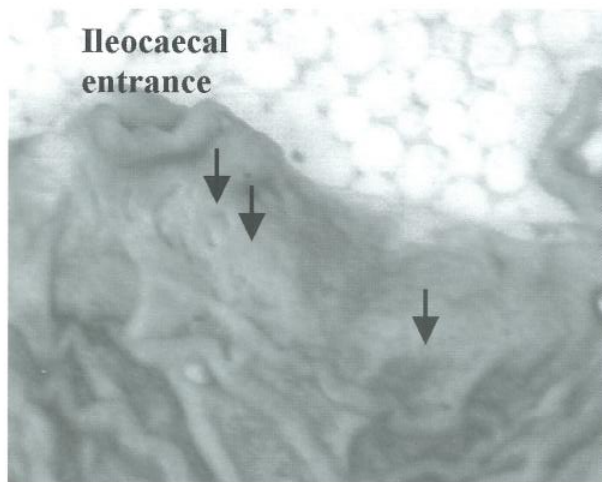


Fig. 1. Peyer's patches of mucosa-associated lymphoid tissue of a three-month-old calf with opening of lymphoglandular complexes (arrows) at ileocaecal entrance.

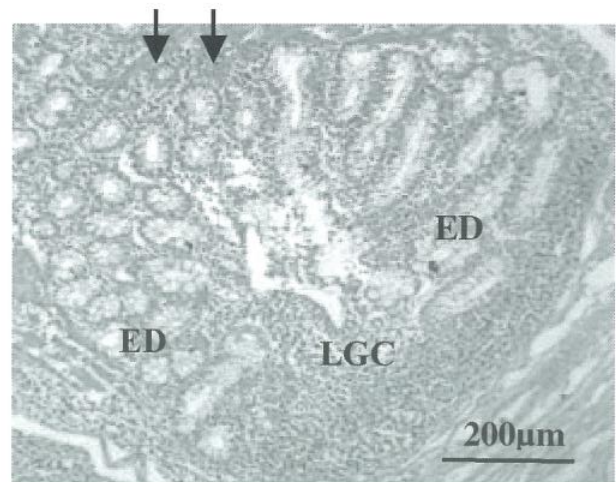


Fig. 3. Histological examination shows that the lymphoglandular complex (LGC) passes through the muscularis mucosae (arrows) and branches into epithelial diverticula (ED) containing intestinal glands. Bar = 200 μ m

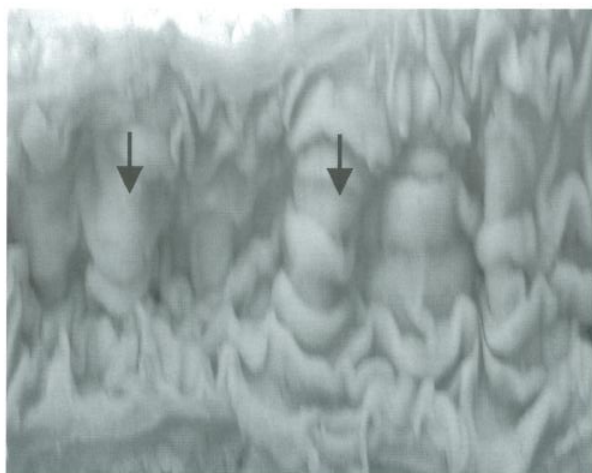


Fig. 2. Peyer's patches of mucosa-associated lymphoid tissue of a three-month-old calf with opening of lymphoglandular complexes (arrows) in the proximal colon.

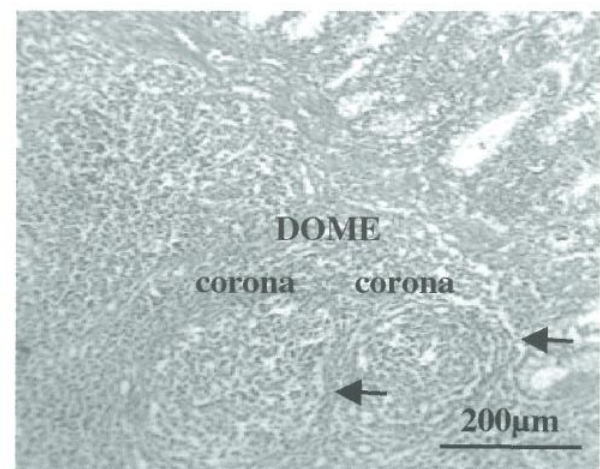


Fig. 4. Histological examination shows the lymphoglandular complex, which consists of lymphoid follicles, a broad dome area, distinct corona area and the interfollicular area (arrows). Bar = 200 μ m

Table 1: Number of Peyer's patches of the large intestine of three-month-old calves

Calf	Caecum	Colon	Rectum
1	1	4	2
2	1	3	0
3	1	3	1

Table 2: The length and width of Peyer's patches of large intestine in three-month-old calves

Calf	Caecum (cm)		Colon (cm)		Rectum (cm)	
	Length	Width	Length	Width	Length	Width
1	4.5	1.2	6.63	2.5	3.4	1.2
2	4.0	1.5	6.66	2.0	0	0
3	3.2	1.5	5.33	2.1	4.1	1.8

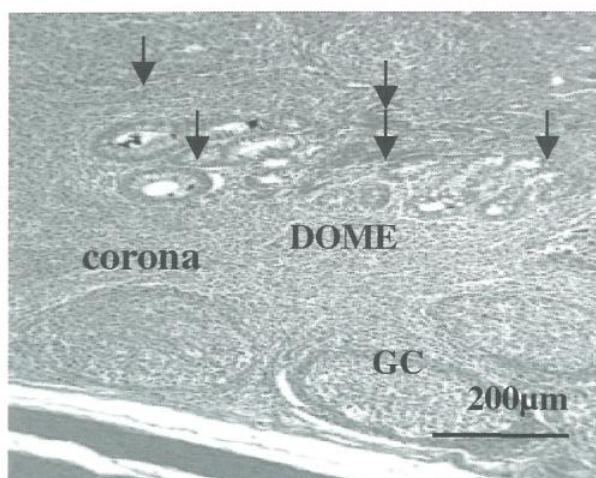


Fig. 5. Histological examination shows location of the lamina propria nodules in the lamina propria. They have distinct dome areas and are surrounded by wide crypts (arrows). One lymphoid follicle has a germinal center (GC) and is surrounded by corona or a diffuse sheet of primary small lymphocytes. Interfollicular area (IFA) is seen between follicles. Bar = 200 μ m

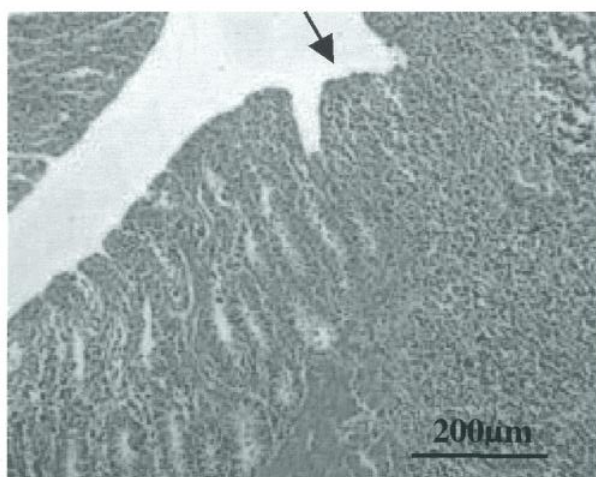


Fig. 6. Histological examination shows the lamina propria nodule with crypts lacking and forming hill-like elevation (arrow). Bar = 200 μ m

Solitary lymphoid follicles were scattered along the colon and rectum. Solitary lymphoid tissue or propria nodules were mainly located in the lamina propria. Their dome like protrusion possessed a modified epithelium. The propria nodules varied in diameter and height in all calves. They were surrounded by three to 10 wide crypts (Figure 5) and were rounded or oval in shape. Lymphoid follicle had one germinal center surrounded by dense paracortical area or diffuse sheets of primary small lymphocytes. Some of the lamina propria lymphoid nodules had crypt lacking and were infiltrated by lymphocytes. These lamina propria nodules formed hill-like elevation (Figure 6). The center of the elevation and epithelium of adjacent wide crypts were lined by distinct follicles associated epithelium. That epithelium was composed of a few enterocytes, cells without well-defined

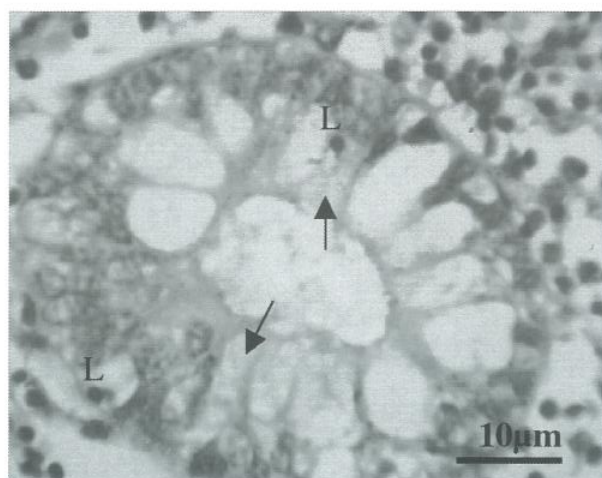


Fig. 7. Histological examination shows the follicle associated epithelium (FAE) of crypt of large intestine. FAE is composed of columnar shaped cells, lacks goblet cells M cell (arrows) and intraepithelial lymphocytes (L). Bar = 10 μ m

brush border, and numerous intraepithelial cells and lacked goblet cells. The number of lymphoid follicles was highly variable between the three calves. Some had few well-defined aggregates. The numbers of lymphoid follicles in proximal colon increased again in the distal portion of the colon. The number of lymphoid follicles varied at different regions. Follicles were most numerous in the caecum, averaging 2.7–4.3 follicles for all the calves examined. The number of follicles in the rectum was lowest, averaging 0.8 to 1.0 follicles.

A comparison of the mean number of follicles counted in caecum, colon and rectum in all calves is presented in Table 3. The size of the follicles varied within the different parts of the large intestine in all calves of the same age (Tables 4 and 5). Although the length of lymphoid follicles of colon in calf 1 and calf 2 was significantly different ($p < 0.05$) from the other parts of large intestine, the length of lymphoid follicles of caecum in calf 3 was significantly different ($p < 0.05$) from the others. The width of lymphoid follicles of colon was significantly different ($p < 0.05$) from that of other parts of large intestine in individuals. Within calves, the width of lymphoid follicles of colon in calf 3 was significantly different ($p < 0.05$) from that of calves 1 and 2.

The follicle-associated epithelium of glandular complex comprised columnar-shaped cells, lacked goblet cell and many intraepithelial lymphocytes and M cell like cells (Figure 7). The epithelium could not be distinguished from the adjacent mucosa. The number of intraepithelial lymphocytes per 50 enterocytes of the crypts was significantly higher ($p < 0.05$) than the intraepithelial lymphocytes of different parts of the large intestine (Table 6). The mean number of intraepithelial lymphocytes of the colon was significantly higher ($p < 0.05$) than other parts of the large intestine in calves 1 and 2. However, the mean number of intraepithelial lymphocytes of the

Table 3: The distribution of lymphoid follicles at different parts of the large intestine in three-month-old calves

Calf	Caecum mean \pm SEM	Colon mean \pm SEM	Rectum mean \pm SEM
1	2.7 \pm 1.4 ^{a, z}	2.3 \pm 0.0 ^{b, y}	0.8 \pm 0.2 ^{c, z}
2	3.7 \pm 0.6 ^{a, y}	3.2 \pm 0.2 ^{b, x}	0.8 \pm 0.2 ^{c, y}
3	4.3 \pm 0.9 ^{a, x}	3.2 \pm 0.7 ^{b, x}	1.0 \pm 0.4 ^{b, x}

a, b, c means with different superscripts within a row were significantly different at $p < 0.05$.

x, y, z means with different superscripts within a column were significantly different at $p < 0.05$.

Table 4: The mean length of lymphoid follicles at different parts of the large intestine in three-month-old calves

Calf	Caecum mean \pm SEM	Colon mean \pm SEM	Rectum mean \pm SEM
1	65.5 \pm 2.8 ^{b, z}	103.2 \pm 3.9 ^{a, y}	56.0 \pm 2.4 ^{c, y}
2	79.9 \pm 3.7 ^{b, y}	108.5 \pm 2.7 ^{a, x}	73.0 \pm 4.1 ^{c, x}
3	114.7 \pm 5.4 ^{a, x}	101.8 \pm 7.5 ^{b, y}	75.8 \pm 3.3 ^{c, x}

a, b, c means with different superscripts within a row were significantly different at $p < 0.05$.

x, y, z means with different superscripts within a column were significantly different at $p < 0.05$ using ANOVA.

Table 5: The mean width of lymphoid follicles at different parts of the large intestine in three-month-old calves

Calf	Caecum mean \pm SEM	Colon mean \pm SEM	Rectum mean \pm SEM
1	55.5 \pm 2.5 ^{b, y}	70.0 \pm 3.3 ^{a, z}	49.5 \pm 1.8 ^{c, y}
2	69.5 \pm 3.5 ^{c, x}	79.0 \pm 3.9 ^{a, y}	73.0 \pm 3.1 ^{b, x}
3	65.1 \pm 3.2 ^{c, x}	87.0 \pm 3.2 ^{a, x}	70.0 \pm 3.4 ^{b, x}

a, b, c means with different superscripts within a row were significantly different at $p < 0.05$.

x, y, z means with different superscripts within a column were significantly different at $p < 0.05$ using ANOVA.

Table 6: The mean number of intraepithelial lymphocytes at different parts of large intestine in three-month-old calves

Calf	Caecum mean \pm SEM	Colon mean \pm SEM	Rectum mean \pm SEM
1	17.3 \pm 0.6 ^{b, y}	13.6 \pm 0.7 ^{a, y}	10.2 \pm 0.7 ^{b, y}
2	12.0 \pm 0.7 ^{b, z}	14.4 \pm 0.7 ^{a, y}	11.9 \pm 0.5 ^{b, y}
3	28.0 \pm 1.0 ^{a, x}	25.5 \pm 1.0 ^{a, x}	14.6 \pm 0.9 ^{b, x}

a, b, c means with different superscripts within a row were significantly different at $p < 0.05$.

x, y, z means with different superscripts within a column were significantly different at $p < 0.05$ using ANOVA.

caecum in calf 3 was not significantly different ($p > 0.05$) from that of the colon.

In the caecum, small aggregate lymphoid tissues were seen in the submucosa beneath the relatively undifferentiated mucous membrane. The caecal lymphoid patches of calves consisted of lymphoid follicles, each covered by an oval dome. Lymphoglandular complexes were found and comprised submucosal extensions of intestinal glands branching within the submucosal lymphoid nodules. Crypts perforated the muscularis mucosae and entered the submucosal layer. The epithelium of caecal lymphoid tissue contained regularly arranged intraepithelial lymphocytes.

In the colon, aggregates of lymphoid tissues were found in the proximal, middle and distal colon. Colonic lymphoid tissue was organized as both solitary follicles or propria lymphoid nodules and as a lymphoglandular

complex. Fewer follicles were frequently characterised by clefts, which penetrated deep into the submucosa. The colonic cleft appeared to be a modification of typical colonic crypt units. Mostly small, dome-like structures protruded near the bottom of the apparent crypt. Some lymphoid follicles had broad corona and wide interfollicular areas.

The colonic lymphoglandular complex had pore-like depressions of surface epithelium. The epithelium extended and passed through a circular gap in the muscularis mucosae and penetrated the submucosa lymphoid tissue. The number of follicles per lymphoglandular complex varied in different sites of the colon with the follicles in proximal colon generally larger than elsewhere. Follicles in the lymphoglandular complex typically contained germinal centers with numerous tangible body macrophages and centrally oriented corona.

Epithelium diverticula ramified radically into the lymphoid tissue of the complex. Diverticula varied widely in number, size, shape and position. Many diverticula were near the overlying muscularis mucosae but some extended to the deep margins. The epithelium of the proximal colonic lymphoid tissue strongly resembled follicle-associated epithelium observed under a light microscope.

In all calves examined, the lymphoid tissues which were found in the terminal rectum were less of lymphoglandular complexes. Both lymphoid nodules and lymphoglandular complexes had germinal centers. Interfollicular lymphoid tissues were abundant in the submucosa. In some diverticula of the lymphoglandular complex, a distinct epithelium with a few goblet cells was observed. Lymphoid nodules were present in the submucosa and the muscularis mucosae were disrupted and lymphoid tissues extended into the lamina propria beneath the lymphoepithelium region.

DISCUSSION

Peyer's patches of the large intestine were found at different sites of the large intestine. The morphology of gut associated lymphoid tissues of the large intestine of calves examined were similar in the caecum, colon and rectum. In this study, patches like gut associated lymphoid tissues were found at the ileocaecal entrance, the proximal colon and in the terminal rectum. This finding is supported by Carlens, (1928) and Habel, (1960). The distribution of lymphoid tissue of the large intestine is related to various types of nutrition, different consistencies of faeces and the duration of retention in the rectum (Sturgess *et al.*, 2001). Sturgess *et al.* (2001) states that in normal animals, faecal material is present in the post-pelvic region only during defecation, thus the number of lymphoid aggregates is lower in the rectum. The faeces are normally stored in the distal colon proximal to the pelvis, thus the number of lymphoid tissues was higher in that area. Further away from the pelvis towards the ileocaecal junction, the number of lymphoid tissues gradually declined in number. In contrast, in this study the distribution of lymphoid follicles in caecum and proximal colon was significantly higher than in the rectum. Thus, the number of lymphoid tissues is thought to relate with the presence of ingesta in the caecum. The results of this study indicate that lymphoid follicles are distributed over the entire large intestine with a mean density of 3.6 per mm² in the caecum, 2.9 per mm² in the colon and 0.9 per mm² in the rectum. Robinson *et al.* (1973) observed that the mean size of lymphoid follicles of the large intestine in humans was 2 mm in diameter. In this study the mean diameter of lymphoid follicles was 20 µm in the caecum, 25 µm in the colon and 18.6 µm in the rectum. Thus, this study showed that the diameter of lymphoid follicles was less than that of lymphoid follicle of humans. Lymphoid aggregates were distributed throughout the colon with or without germinal centers. This finding is in accordance

with that of Sturgess *et al.* (2001). However, the distribution of lymphoid tissue varied not only from species to species but also from caecum to rectum in the same age and same species and the size of lymphoid follicle and development of the germinal centers were influenced by contact with antigens. In this study, caecal Peyer's patches closely resembled that of the small intestine Peyer's patches in the number of follicles, size of follicles and development of germinal centers and antimesenteric location. In many species, colonic lymphoid tissue is composed of both lamina propria nodules and lymphoglandular complexes. In the lymphoglandular complex, the lymphoid follicles are located below the muscularis mucosae, with crypts near the colonic lumen. In humans, the lymphoglandular complexes penetrate into the crypts and dome-like structures are present above the lymphoid follicles (Kealy, 1976; Langman and Rowland, 1986; O'leary and Sweeney, 1986; Jacob *et al.*, 1987). These findings are similar to our finding in this present study. In the rat, proximal colonic lymphoid tissue is largely populated by immature lymphocytes and the epithelium of these lymphoid tissues resembles follicle-associated epithelium at the light microscopic level (Course *et al.*, 1989).

In the colon of the rat and pig, the lamina propria nodules and lymphoglandular complex have been reported to have functional significances (Bland and Britton, 1984). Liebler *et al.* (1988) mentioned that different types of lymphoid nodules might also be associated with different functions. They described that the increasing number of lymphoglandular complexes depend on age, nutrition or microbial environment. Aleksandersen *et al.* (1990) mentioned that the lymphoid tissue of the large intestine might imply a greater influence of luminal antigen on the maintenance of lymphopoiesis than for the ileal Peyer's patches. In this study, proximal colonic lymphoid tissues had fewer germinal centers and lymphocytes. These lymphocytes were relatively uniformly distributed throughout the follicles. In addition, large cells with clear cytoplasm and centrally located nucleus were found among the lymphoid cells. Some lymphoid tissue of the large intestine had broad follicles and a wide interfollicular area. These characteristics were different from the ileal Peyer's patches and similar to jejunal Peyer's patches, however, crypts were present and they penetrated into the lymphoid tissue and there was also the occurrence of dome with a modified epithelium in these crypts. In some mammals especially the pig, horse and dog, anal lymphoid tissues or anal tonsils occurred in the anal canal (Orthmann, 1960). While anal tonsils in the dog and swine develop after birth, the lymphoid nodules in the rectal mucosa of ruminants are already present at birth (Carlens, 1928, Orthmann 1960).

Both lamina propria nodules and lymphoglandular complex of the large intestine have specialized epithelium. The follicle-associated epithelium on the lamina propria nodules and lymphoglandular complex consists of cells

compatible with M cells on domes of small intestinal Peyer's patches. Few studies have focused on the number of intraepithelial lymphocytes in the large intestine; however, Dobbins (1986) reported 5% per 100 epithelial cells in man, and Atkin and Schofield (1972) reported 2% per 100 epithelial cells in dog. Sturgess *et al.* (2001) mentioned that in the cat, the number of intraepithelial lymphocytes per 100 epithelial cells was similar to those in man. However, in this study, the number of intraepithelial lymphocytes per 100 epithelial cells varied in different sites of the large intestine. The different numbers of intraepithelial lymphocytes also exist between small and large intestine at the same age. The ability of intraepithelial lymphocytes is proliferation in response to mitogen stimulation (Wilson *et al.*, 1986). In normal animals, the indigenous enterobacteria are unable to penetrate the mucosal barrier. Thus, the mucosal lymphoid tissues normally provide protection against potentially pathogenic indigenous bacteria.

REFERENCES

- Aleksandersen, M., Hein, W., Landsverk, T. and Mc Clure, S. (1990). Distribution of lymphocytes subsets in the large intestinal lymphoid follicles of lambs. *Immunology* **70**: 391-397.
- Atkin, A. and Schofield, G. (1972). Lymphoglandular complex in the large intestine of dog. *Journal of Anatomy* **113**: 169-178.
- Bland, P.W. and Britton, D.C. (1984). Morphological study of antigen sampling structure in rat large intestine. *Infection and Immunity* **43**: 693-699.
- Carlens, O. (1928). Studien uber das lymphatische gewebe des Darmkanalis bei einigen haustieren, mit besonderen Berücksichtigung der embryonalen Entwicklung, der Menenver- haltnisse im Dunndarm des Rindes. *Z. Anat. Entwicklung Ges* **86**: 393-492.
- Course, D.A., Perry, G.A., Murphy, B.O. and Sharp, J.G. (1989). Characteristics of submucosal lymphoid tissue located in the proximal colon of the rat. *Journal of Anatomy* **162**: 53-65.
- Dobbins, W. (1986). Human intestinal intraepithelial lymphocytes. *Gut* **27**: 972-985.
- Gebert, A. and Bartels H. (1995). Ultrastructure and protein transport of M cells in the Rabbit Caecal Patch. *The Anatomical Record* **241**: 487-495.
- Habel, R. (1960). Untersuchungen uber das Vorkommen von lymphatischen darmkry pten in der Tunca submucosa des darmes von Schwein, Rind. Schaf Hand und katze. *Anat. Anz* **109**: 7-27.
- Jacob, E., Baker, S.J. and Swaminathan, S.P. (1987). M cells in the follicle-associated epithelium in the human colon. *Histopathology* **11**: 941-952.
- Kealy, W.F. (1976). Colonic lymphoid-glandular complex (microbursa) nature and morphology. *Journal of Clinical Pathology* **29**: 241-244.
- Langman, J.M. and Rowland, R. (1986). The number and distribution of lymphoid follicles in human large intestine. *Journal of Anatomy* **194**: 189-194.
- Liebler, E.M. (1986). Mucosa-associated lymphoid nodules in the large intestine of young calves: a morphologically study with special regard to lymphoepithelial relationship and epithelial ultrastructure. M.S Thesis. Iowa State-University. Ames.
- Liebler, E.M., Pohlenz, J.F and Woode, G.N. (1988). Gut-associated lymphoid tissue in the large intestine of calves distribution and histology. *Veterinary Pathology* **25**: 503-508.
- O'Leary, A.D. and Sweeney, E.C. (1987). Lymphoglandular complex of the normal colon. Histochemistry and immunochemistry. *Irish Journal of Medical science* **156**: 142-148.
- Orthmann, R. (1960). Uber den lymphatischen apart der Analregion und die sogenannte. Analtonsille bei Saugetieren. *Zeitchrift fur Anatomia und Entwicklungsgeschichte* **121**: 459-477.
- Owen, R.L. (1983). And now pathophysiology of M cells: good news and bad news from Peyer's patches. *Gastroenterology* **85**: 468-470.
- Perry, G.A. and Sharp, J.G. (1988). Characterization of proximal colonic lymphoid tissue in the mouse. *Anatomy Record* **220**: 305-312.
- Pohlenz, J.F., Bolin, S. and Moenning, V. (1986). Morphologic lesion in experimental mucosal disease reproduced by dual infection, pp 39-41 9th Intern Sym "Infection of the Reproductive System of Some Domestic Animal Species" Perugia, Italy.
- Ramsey, F.K (1956). Pathology of mucosal disease of cattle. PhD thesis, Iowa State University. Ames IA.
- Robinson, M. J., Pardon, S. and Rywlin, A. (1973). *Enterocolitis lymphofollicularis*. *Archives of Pathology* **96**: 311-315.

- Sturgess, C.P., Canfield, P.J., Gruffydd-Jones, J.J. and Stokes, C.R. (2001). A gross and microscopical morphometric evaluation of feline large intestinal anatomy. *Journal of Comparative Pathology* **124**: 255-264.
- Wilson, A., Stoke, C. and Bourne, F. (1986). Morphological and functional characteristics of isolated porcine intraepithelial lymphocytes. *Immunology* **59**: 109-113.