

DIAGNOSTIC APPROACH TO A FUNCTIONAL ADRENAL TUMOUR IN A SHIH-TZU POODLE MIX

L. P. Tan¹, H.F. Thong² and S.Y. Lim^{1*}

¹Faculty of Veterinary Medicine, Universiti Putra Malaysia, UPM, Serdang, Selangor, Malaysia.

²Universiti Veterinary Hospital, Faculty of Veterinary Medicine, Universiti Putra Malaysia, UPM, Serdang, Selangor, Malaysia.

SUMMARY

Hyperadrenocorticism is the excessive production of cortisol by the adrenal cortex. 15-20% of hyperadrenocorticism in dogs may be due to functional adrenal tumour. Here we present a case of functional adrenal tumour in a 10 years old Shih-Tzu Poodle mixed-breed dog that was presented to University Veterinary Hospital, Universiti Putra Malaysia. Physical examination findings include multiple cutaneous myiasis, a pendulous abdomen with comedones on the ventral thoracic region and thinning of the skin. Clinical signs shown were polyuria, polydipsia and polyphagia. Serum biochemistry result showed elevated alkaline phosphatase enzyme of 5 folds. Urinary specific gravity was minimally concentrated (1.015). Radiography showed generalised hepatomegaly. Meanwhile, ultrasonography showed unilateral enlargement of the right adrenal gland with mineralisation. Invasion of the right adrenal gland into the caudal vena cava was observed. A differentiation test (high-dose dexamethasone suppression test) was performed and a lack of suppression of the cortisol level was observed. Based on the appropriate clinical signs and physical examination findings, elevated alkaline phosphatase enzyme, minimally concentrated urinary specific gravity, generalised hepatomegaly, unilateral adrenal gland enlargement, and high-dose dexamethasone suppression test, a diagnosis of functional adrenal tumour was made.

Key words: adrenomegaly, functional adrenal tumour, hepatomegaly, polydipsia, polyuria

INTRODUCTION

Hyperadrenocorticism (HAC) is the hyperactivity of the adrenal cortices and it can occur iatrogenically or spontaneously (Herrtage, 2004). Spontaneously occurring HAC are divided into pituitary-dependent hyperadrenocorticism (PDH) and functional adrenocortical tumours (FAT). More than 80% of HAC in dogs occur due to PDH while the remaining occur due to FAT (Herrtage, 2004).

PDH is due to excessive adrenocorticotrophic hormone (ACTH) secretion by a pituitary adenoma (Rijnberk and Kooistra, 2010). FAT on the other hand causes hypercortisolism which is ACTH-independent (Rijnberk and Kooistra, 2010). Common clinical signs associated with HAC are polyuria, polydipsia, polyphagia, abdominal distention, muscle wasting and bilateral truncal alopecia (Herrtage, 2004). HAC often have an insidious onset and is slowly progressive (Herrtage, 2004). HAC is usually screened using ACTH stimulation test. Whereas low-dose dexamethasone suppression test (LDDST) and high-dose dexamethasone suppression test (HDDST) are used as differentiating tests between PDH and FAT (Behrend *et al.*, 2013). Here we report a case of a dog with FAT, diagnosed based on a combination of clinical signs, minimum database, radiography, ultrasonography and HDDST.

CASE REPORT

A 10 years old, intact female Shih Tzu-Poodle mixed dog was presented to University Veterinary

Hospital (UVH), Universiti Putra Malaysia in November, 2015 for the primary complaint of cutaneous myiasis after the dog went missing for two weeks prior to presentation. Physical examination revealed a temperature of 38.6°C, heart rate of 156 beats per minute and respiration rate of 36 breaths per minute. The dog weighed 8.6 kg with BCS of 1/5. Mucous membrane was pink with CRT of 2 sec. There were multiple maggot wounds on the forelimbs and hindlimbs. A pendulous abdomen with comedones on the ventral thoracic region was present. Thinning of the skin with prominent blood vessels was observed on the ventral abdomen.

The dog was subsequently hospitalised for management of the multiple maggot wounds. During hospitalisation, polyuria, polydipsia and polyphagia were observed. Based on the clinical signs, the differential diagnoses included HAC, diabetes mellitus and chronic kidney disease. Further diagnostic plans included minimum database (complete blood count [CBC], serum biochemistry and urinalysis), abdominal radiography and ultrasonography.

CBC revealed regenerative left shift leukocytosis and mild non-regenerative anemia (Table 1). Serum biochemistry revealed elevated Alkaline Phosphatase activity (550 U/L; reference range: 40-100 U/L). Urine was also minimally concentrated (urinary specific gravity = 1.015). Right lateral abdominal radiograph showed blunting of caudoventral liver margins with extension beyond the costal arch, and caudal displacement of the gastric axis (Figure 1). The radiological diagnosis was generalized hepatomegaly with differential diagnoses including hepatic congestion, steroid hepatopathy, vacuolar hepatopathy, reactive hepatopathy, inflammatory and infiltrative hepatic diseases, and primary and metastatic neoplasia. Abdominal ultrasonography revealed

* Corresponding author: Dr. Lim Sue Yee (S.Y. Lim);
Phone No: +603 8609 3905; Fax No: +603 8947 1971;
Email: sueyee@upm.edu.my

Table 1. Selected complete blood count parameters

Complete blood count		Results	Reference range
Erythrocytes (RBC)	x10 ¹² /L	3.57	5.5-8.5
Haemoglobin	g/L	113	120-180
PCV	L/L	030	0.35-0.55
Reticulocytes	/100RBC	0.5	0.5-1.5
Leucocytes (WBC)	x10 ⁹ /L	19.5	6.0-17.0
Band Neutrophils	x10 ⁹ /L	0.39	<0.3
Segmented Neutrophils	x10 ⁹ /L	14.04	3.0-11.5
Lymphocytes	x10 ⁹ /L	1.56	1.5-4.8
Monocytes	x10 ⁹ /L	2.93	0.2-1.4
Eosinophils	x10 ⁹ /L	0.59	0.1-1.3
Basophils	x10 ⁹ /L	0	Rare

RBC, Red blood cell; PCV, packed-cell volume; WBC, White blood cell

an enlarged right adrenal gland with a maximal thickness of 1.53 cm (normal < 0.6 cm) (Choi *et al.*, 2011). The right adrenal gland had irregular contours as well as a hyperechoic nidus with acoustic shadowing suggestive of mineralization (Figure 2). Colour Doppler examination showed invasion of the right adrenal gland into the adjacent caudal vena cava (Figure 3). The left adrenal gland could not be visualized. This could be due to contralateral adrenal gland atrophy or interference from abdominal gas.

Based on the appropriate clinical signs and physical examination findings, elevated ALP, minimally concentrated urinary specific gravity, generalized hepatomegaly and unilateral adrenal gland enlargement, a tentative diagnosis of FAT was made. To confirm our diagnosis, HDDST was performed. Baseline, 4- and 8-hour serum cortisol were > 276 nmol/L indicating a lack of suppression. Thus, a final diagnosis of FAT was made.

DISCUSSION

Adrenal tumours can be functional or non-functional. FATs are hormonally active and patients usually are presented with clinical signs (Rijnberk and Kooistra, 2010). Non-functional adrenal tumours however, are endocrinologically silent without clinical signs (Rijnberk and Kooistra, 2010). Examples of FATs are such as adrenocortical carcinomas, adrenocortical adenomas and pheochromocytomas. Examples of non-functional adrenal tumours are incidentaloma and myelolipoma. In this case report, the patient showed clinical signs consistent with HAC and HDDST revealed a lack of suppression, indicating that the adrenal tumour seen in this case was a functional tumour. A biopsy of the mass was not performed due to its invasiveness.

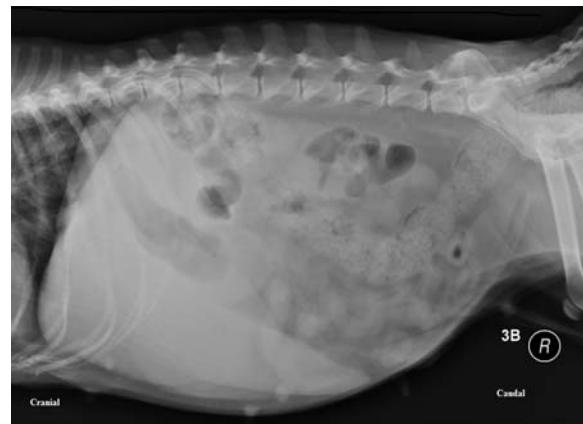

Figure 1. Right lateral abdominal radiograph shows blunting of caudoventral liver margins with extension beyond the costal arch, and caudal displacement of the gastric axis indicating hepatomegaly. Cranial to the left, caudal to the right.

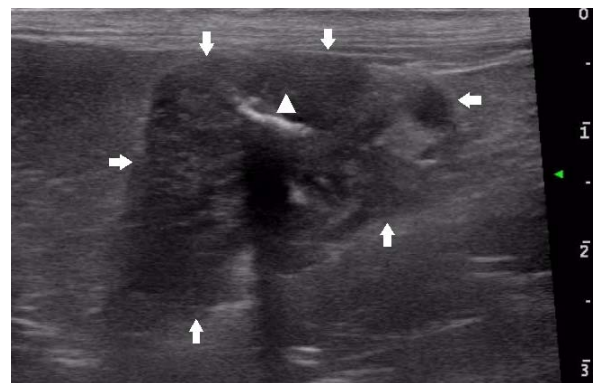


Figure 2. Ultrasonographic image of the enlarged right adrenal gland (arrows) with maximal thickness of 1.53 cm. The right adrenal gland had irregular contours as well as a hyperechoic nidus (arrow head) with acoustic shadowing suggestive of mineralization. Cranial to the left, caudal to the right, ventral to the top.

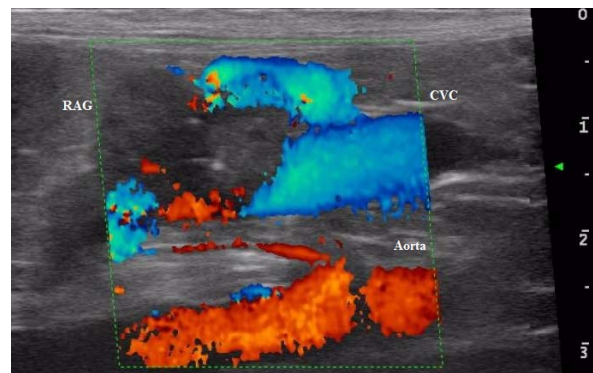


Figure 3. Colour Doppler examination of the right adrenal gland (RAG) shows invasion of the right adrenal gland into the adjacent caudal vena cava (CVC). Cranial to the left, caudal to the right, ventral to the top.

Ultrasonography is very useful for the investigation of adrenal tumours. The criteria for malignancy of adrenal tumour on ultrasonography include adrenal gland thickness of > 4 cm, irregular contours and local vascular invasion (Besso *et al.*, 1997). Two criteria of malignancy (irregular contours and local invasion of the caudal vena cava) were seen in this case. Mineralization was also observed and this is seen in cases of adrenal adenomas or carcinomas, but when found alone does not necessarily represent a sign of malignancy (Besso *et al.*, 1997).

Based on the clinical signs, minimum database, radiographic and ultrasonographic findings, FAT was highly suspected in this case. Therefore HDDST (instead of ACTH stimulation test or LDDST) was deemed more beneficial as the differentiation test between PDH and FAT.

The best treatment for FAT is adrenalectomy as it carries the best prognosis when the tumour is successfully removed (Herrtage, 2004). However, it has been reported that intraoperative and postoperative complications occur in 15 and 51% of dogs, respectively (Kyles *et al.*, 2003). Trilostane is the next best option if adrenalectomy is not performed, as it has less adverse effect than mitotane (Arenas *et al.*, 2014). The adrenal tumour and metastatic mass(es) will often reduce in size due to cytotoxic effects of mitotane, but some tumour continue to grow despite mitotane treatment (Herrtage, 2004).

CONCLUSION

A combination of diagnostic methods is important for the diagnosis of FAT. ACTH stimulation and LDDST are not necessarily the first tests to be performed. It is important to consider the differential diagnoses in guiding choices of diagnostic tools.

ACKNOWLEDGMENT

The authors wish to thank the staff of UVH for their assistance in this case.

CONFLICT OF INTEREST

None of the authors have any potential conflicts of interest to declare.

REFERENCES

- Arenas, C., Melian, C., and Perez-Alenza, M. D. (2014). Long-term survival of dogs with adrenal-dependent hyperadrenocorticism: a comparison between mitotane and twice daily trilostane treatment. *Journal of Veterinary Internal Medicine*. 28, 473-480.
- Behrend, E. N., Kooistra, H. S., Nelson, R., Reusch, C. E., and Scott-Moncrieff, J. C. (2013). Diagnosis of spontaneous canine hyperadrenocorticism: 2012 ACVIM consensus statement (small animal). *Journal of Veterinary Internal Medicine*. 27, 1292-1304.
- Besso, J. G., Penninck, D. G., and Gliatto, J. M. (1997). Retrospective ultrasonographic evaluation of adrenal lesions in 26 dogs. *Veterinary of Radiology and Ultrasound*. 38, 448-455.
- Choi, J., Kim, H., and Yoon, J. (2011). Ultrasonographic adrenal gland measurements in clinically normal small breed dogs and comparison with pituitary-dependent hyperadrenocorticism. *Journal of Veterinary Medical Science*. 73, 985-989.
- Herrtage, M. E. (2004). Canine Hyperadrenocorticism. In: *BSAVA Manual of Canine and Feline Endocrinology*. Mooney, C. T. and Peterson, M. (Eds.) 3rd. ed., BSAVA, Gloucester. pp. 150-171.
- Kyles, A. E., Feldman, E. C., De Cock, H. E., Kass, P. H., Mathews, K. G., Hardie, E. M., and Gregory, C. R. (2003). Surgical management of adrenal gland tumors with and without associated tumor thrombi in dogs: 40 cases (1994-2001). *Journal of American Veterinary Association*. 223, 654-662.
- Rijnberk, A., and Kooistra, H. S. (2010). *Clinical Endocrinology of Dogs and Cats: An Illustrated Text*. Schluetersche, Germany.