

INCLUSION BODY HEPATITIS IN A FLOCK OF COMMERCIAL BROILER CHICKENS

M. Hair-Bejo

*Faculty of Veterinary Medicine, Universiti Putra Malaysia,
43400 UPM, Serdang, Selangor, Malaysia*

SUMMARY

Thirty-four-day-old broilers from a flock of chickens in a commercial farm in Perak with history of poor growth and high mortality were submitted for necropsy. On necropsy, mild to moderate enlargement of liver with pale, friable and fatty changes in appearance, and areas of haemorrhage and congestion were observed. The kidney was pale and slightly enlarged. Histologically, numerous eosinophilic and basophilic, round or irregular-shaped intranuclear inclusion bodies were observed in the hepatocytes. The hepatic parenchyma was moderately degenerated and necrotised. Moderate congestion with areas of haemorrhage and moderate to severe infiltration of mononuclear inflammatory cells were also observed in the liver.

Keywords: Inclusion body hepatitis (IBH), commercial broiler chickens, intranuclear inclusion body, group I adenovirus.

INTRODUCTION

Inclusion body hepatitis (IBH) is a disease of chickens caused by group I adenovirus. It is characterized by a sudden onset of mortality peaking after 3-4 days of infection and usually ending on the fifth day, but with infection occasionally continuing for 2-3 weeks. Morbidity is low and sick birds adopt a crouching position with ruffled feathers and die within 48 hours or recover (Calnek *et al.*, 1991). Mortality may reach 10% and occasionally go up to 30%. It is normally seen in meat producing birds at 3-7 weeks of age, but has been reported in birds as young as 7-day old and as old as 20 weeks.

IBH was first reported by Helmboldt and Frazier (1963) in the USA and since then, the disease has spread worldwide and has also been observed in other avian species such as turkeys, geese, pheasants, psittacines and quails (Cowen, 1992; Singh *et al.*, 1995). Transmission may be vertical through the embryonated egg or horizontal, especially by direct fecal contact of the infected chickens and may involve fomites. There is evidence that in an integrated broiler operation, disease occurs in chickens from certain breeder flocks (Macpherson *et al.*, 1974). The role of IBH in the country is little known; however, the high mortality with poor broiler performance during disease outbreak will definitely cause a significant impact on the poultry industry in the country. This paper reports a case of IBH in a flock of broiler chickens.

CASE HISTORY

Seven, 34-day-old broilers from a flock of 36,700 chickens in a commercial farm in Perak, with a history of poor growth and high mortality (9.65%), were submitted

for necropsy. The average body weight of the chickens at market age of 37 to 49 days was 1.85kg, whilst the feed conversion ratio was 2.15. The broilers were reared under an open house system with slathered floor in a rubber estate. The birds were vaccinated against infectious bronchitis and Newcastle disease through intraocular route at 6 days of age. At the same time, the chickens were inoculated subcutaneously with inactivated Newcastle disease vaccine. At day 14, the birds were vaccinated against infectious bursal disease through drinking water. Polyvitamins were given at day-old and from days 3 to 5 of age, the chicks were medicated with colistrin and florfenicol. Amoxicillin was given from days 8 to 11 of age followed by norfloxacin and tylosin at days 17 to 21 of age. By day 20 of age until the market age, vitamins were given once a day. On necropsy, samples of liver were fixed in 10% buffered formalin and processed for histological examination.

RESULTS

On necropsy, mild to moderate enlargement of liver with pale, friable and fatty changes appearance, and areas of haemorrhages and congestion were observed (Fig. 1). The kidney was pale and slightly enlarged. Two chickens showed typical lesions of complicated chronic respiratory disease (CCRD) with fibrinous perihepatitis, pericarditis and airsacculitis. On histological examination of the liver numerous eosinophilic and basophilic, round or irregular shaped intranuclear inclusion bodies were observed in the hepatocytes (Fig. 2, 3). The hepatic parenchyma was moderately degenerated and necrotised. Moderate congestion with areas of haemorrhages and moderate to severe infiltration of mononuclear inflammatory cells were also observed in the liver.

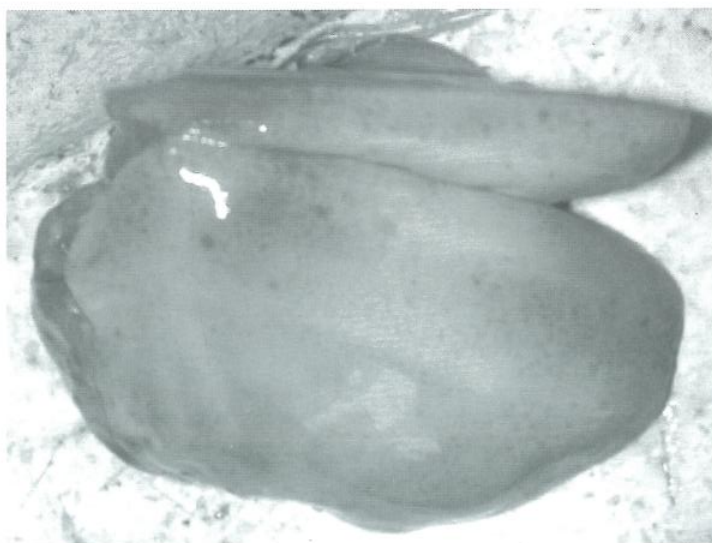


Fig. 1: Swollen, pale and friable liver of 34-day-old broiler chicken with inclusion body hepatitis (IBH).

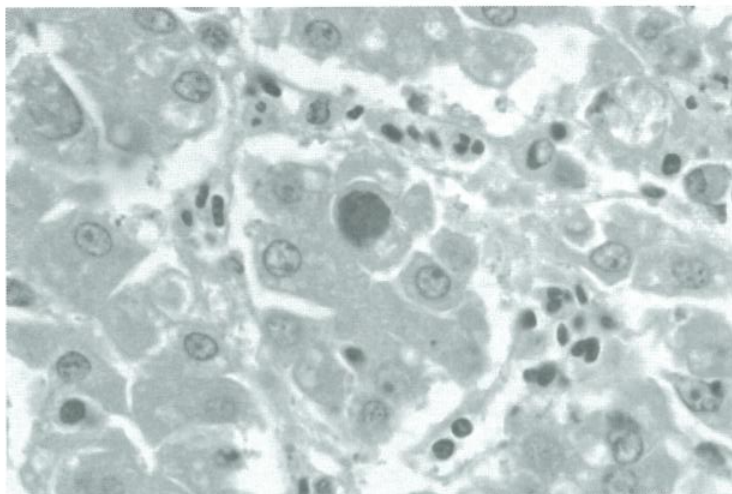


Fig. 2: Large basophilic intranuclear inclusion body in the hepatocytes of 34-day-old broiler chicken with inclusion body hepatitis (IBH), HE, 1000X.

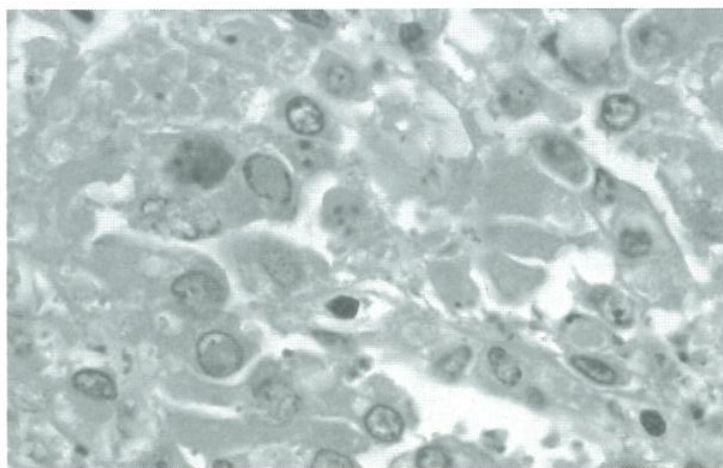


Fig. 3: Eosinophilic intranuclear inclusion bodies in the hepatocytes of 34-day-old broiler chicken with inclusion body hepatitis (IBH), HE, 1000X.

DISCUSSION

A number of adenovirus serotypes have been isolated from IBH outbreaks. Similarly the virus may also be isolated from healthy chickens (Cowen, 1992; Kefford *et al.*, 1980; Grimes *et al.*, 1978). Thus, there is conflicting evidence on the role of the group I adenoviruses as primary pathogens in nature. This is in contrast with the clear association with disease of the group II and egg drop syndrome viruses. However, there is growing evidence to suggest that the group I adenoviruses only play a role as secondary pathogens associated with other viruses such as chicken anaemia virus (CAV) and infectious bursal disease virus (IBDV). Immunosuppression produced by IBDV and CAV was found to aid in an increased incidence of IBH and death (Calnek *et al.*, 1991). However, outbreaks of IBH in the absence of IBD have been reported in some countries such as in Australia and New Zealand (Reece *et al.*, 1986; Christensen and Saifuddin, 1989).

A virulent strain of adenovirus isolated from IBH in broiler chicken flocks causes severe lymphocytic depletion in the bursa, thymus and spleen in both the commercial broiler and specific pathogen free chicken compromising the immunological capability of the infected chickens (Saifuddin and Wilks, 1992). It has been reported that the basophilic intranuclear inclusion bodies in the hepatocytes of chickens with IBH contain numerous adenoviruses when examined under transmission electron microscopy, whilst the eosinophilic inclusions contain only fibrillar granular material and filaments. The eosinophilic inclusions may represent a degenerative process, an early stage in the formation of virus, or a late stage after the virus has left the nucleus (Riddell, 1987). Vaccination against IBH is complicated by the fact that there are numerous serotypes of this virus and the primary role for the group I adenoviruses in disease outbreak has not been established. IBH has also been reported to be associated with naturally occurring outbreaks of hydropericardium syndrome (Abe *et al.*, 1998), respiratory disease (Dhillon and Kibenge, 1987), necrotizing pancreatitis (Ota *et al.*, 1999), and gizzard erosion (Ono *et al.*, 2003). The viruses are resistant to lipid solvents such as ether and chloroform, sodium deoxycholate, trypsin, 2% phenol and 50% alcohol, but they are inactivated by a 1:1000 concentration of formaldehyde (Calnek *et al.*, 1991).

REFERENCES

- Abe, T., Nakamura, K., Tojo, H., Mase, M., Shibahara, T., Yamaguchi, S. and Yuasa, N. (1998). Histology, immunohistochemistry and ultrastructure of hydropericardium syndrome in adult broiler breeders and broiler chicks. *Avian Dis.* **42**:606-612.
- Calnek, B.W., John Barnes, H., Beard, C.W., Reid, W.M. and H.W. Yoder, Jr. (1991). In: *Diseases of Poultry*, 9th. Ed. Ames, Iowa, USA: Iowa State University Press. pp. 552-563.
- Christensen, N.H. and Saifuddin, M. (1989). A primary epidemic of inclusion body hepatitis in broilers. *Avian Dis.* **33**:622-630.
- Cowen, B.S. (1992). Inclusion body hepatitis-anaemia and hydropericardium syndromes: aetiology and control. *World's Poultry Science Journal* **48**(3):247-254.
- Dhillon, A.S. and Kibenge, F.S.B. (1987). Adenovirus infection associated with respiratory disease in commercial chickens. *Avian Dis.* **31**:654-657.
- Grimes, T.M., Fletcher, O.J. and Munnell, J.F. (1978). Comparative study of experimental inclusion body hepatitis of chickens caused by two serotype of avian adenoviruses. *Vet. Pathol.* **15**(2):249-63.
- Helmboldt, C.F. and Frazier, M.N. (1963). Avian hepatic inclusion bodies of unknown significance. *Avian Dis.* **7**:446-450.
- Kefford, B., Borland, R., Slattery, J. F. and Grix, D.C. (1980). Serological identification of avian adenoviruses isolated from cases of inclusion body hepatitis in Victoria, Australia. *Avian Dis.* **24**(4):998-1006.
- Macpherson, I., McDougall, J.S. and Laursen-Jones, A.P. (1974). Inclusion body hepatitis in a broiler integration. *Vet. Rec.* **95**:286-289.
- Ono, M., Okuda, Y. Yazawa, S., Imai, Y., Shibata, I, Sato S. and Okada, K. (2003). Adenoviral gizzard erosion in commercial broiler chickens. *Vet. Pathol.* **40**:294-303.
- Ota, M., Goryo, M., Kawasaki, T., Shimaoka, M., and K. Okada (1999). Stunting and inclusion body pancreatitis with atrophy of the pancreas due to fowl adenovirus in broiler chicks. *J. Jap. Soc. Poult. Dis.* **35**:76-80.
- Reece, R.L., Barr, D.A., Grix, D.C. Forsyth, W.M, Condon, R.J. and Hindmarsh, M. (1986). Observations on naturally occurring inclusion body hepatitis in Victorian chickens. *Australian Veterinary Journal* **63**:201-202.
- Riddell, C. (1987). In: *Avian Histopathology*, 1st ed. The American Association of Avian Pathologists. pp 57-65.

Saifuddin, M. and C.R. Wilks (1992). Effects of fowl adenovirus infection on the immune system of chickens. *J. Comp. Pathol.* **107**(3):285-94

Singh, A., Oberoi, M.S. and B. Singh (1995). Pathogenicity of quail's inclusion body hepatitis virus (avian adenovirus-1) for Japanese quails and broiler chicks. *Vet. Res. Commun.* **19**(6):545-51.