

*Jurnal Veterinar*

*Malaysia*

ISSN 0128-2506

Vol. *32* No. *1* (July) *2020*



**Veterinary Association Malaysia**

## HORSES WITH PARAPHIMOSIS RETURN TO NORMAL BREEDING ACTIVITIES AFTER MEDICAL TREATMENT

S.K.TMUMEN\* and M.M. ELARBI

Department of Surgery and Theriogenology, Faculty of Veterinary Medicine, University of Tripoli, Libya

### SUMMARY

Paraphimosis is the inability of the horse to retract the penis into the prepuce. Trauma to the male genital area is a common cause for paraphimosis. 3 stallions with paraphimosis were presented to the teaching hospital at College of Veterinary Medicine at University of Tripoli, with clinical signs of general fatigue, dullness and protruded penis and obvious swellings on the penis. Other clinical signs include. On the history report, the average age of the stallions was 6 years old with penile swelling age ranged from 3 to 6 weeks old. For treatment, the penile swelling was first washed and immersed in an antiseptic solution 1.5% Potassium permanganate (PP) for 10 minutes once a day, followed by manual massage to reduce oedema, after that, an antibacterial ointment was applied to the lesions (Fucidin ointment). In addition, systemic anti-inflammatory and antibiotic was prescribed to help reduce pain and swelling. The penile swelling in all affected stallions were reduced after twenty-two days from the initial of treatment.

Keywords: Stallion, Penis, paraphimosis, haematoma, male genitalia

### INTRODUCTION

Paraphimosis is the inability of the horse to retract its penis into the preputial cavity. It commonly occurs in stallions as a result of trauma to the genital area, other causes such as penile innervation damage, infectious diseases and some medications were reported (Jörg & John., 2012). The swelling, regardless of its site, interferes with venous and lymphatic drainage and causes the penis to protrude and stay out of the prepuce (Blanchard; 2003; Brinsko, 2007). Injuries to the penis and prepuce are often the result of breeding accidents and fights with other horses (Walker & Vaughan 1980). Paraphimosis ranges from moderate to severe and most of the affected horses suffer from erectile dysfunction and cannot fully retract and maintain the penis within the preputial cavity (Neely, 1980; Henning, 1956)

The longer the penis remain prolapsed the more lymphatic and venous drainage are compromised, resulting in further oedema in the internal preputial lamina (Memon, 1988). As the internal preputial lamina swells, the preputial ring constricts, and drainage will be decreased. As a result, the part of the penis distal to the ring enlarged and become heavier, and more swollen. Moreover, in long-standing cases, the pendulous weight of the prolapsed penis and prepuce can damage the internal pudendal nerves, resulting in permanent penile paralysis (Blanchard, 2003).

Even in the short-term cases, if not protected, the exposed epithelium of the penis and prepuce becomes excoriated, and the area might slough because of pressure necrosis. Moreover, the penis loses its normal telescoping action or elasticity because of fibrosis (Blanchard, 2003). The case report described a successfully medical treatment of paraphimosis.

### CASE REPORT

Three thoroughbred stallions with average age of 6 years were included in the study. All cases presented with a paraphimosis as a result of penile swelling. Based on the history report, the cause of all of the swellings was trauma during training.

#### Treatment Regimen

Initially, the penis and prepuce were thoroughly cleaned and inspected visually and manually to determine the extent of lesion (Figure 1).

Reduction of penile and preputial tissue oedema were attempted by using an antiseptic solution of 1.5%



**Figure1. Horses with paraphimosis as a result of trauma. Notice the swelling the dorsal aspect of the pines on both cases, which prevents the pines from returning into the prepuce and caused it to be protruded.**

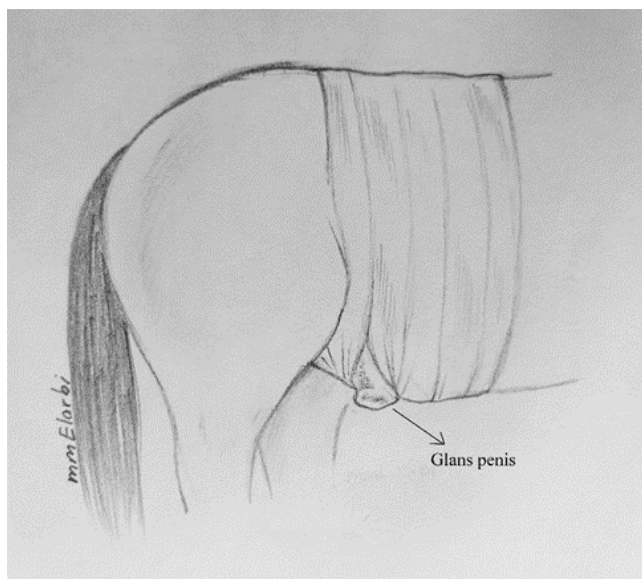
Corresponding author :Samer Khalifa Tmumen (S.K. Tmumen);  
Phone No : 00218927430454; Email: samer2003@yahoo.com



Editorial history  
Paper received: 2<sup>nd</sup> March 2020  
Accepted for publication: 19<sup>th</sup> June 2020  
Issue Online: July 2020

potassium permanganate (PP). The penis was immersed in PP solution for 10 minutes, then dried thoroughly with clean towel. After drying an antibacterial ointment was applied (Fucidin Ointment 2%, Leo Laboratories Limited, United Kingdom Sodium Fucidin 20 mg (Leion) around the penis and preputial tissue. The ointment application starts distally at the glans penis and ends up proximally in order to refresh the penile tissues and reduce the amount of fluid trapped beneath the swelling. The PP solution used once a day for 3 days, while the antibiotic ointment continues 2 to 3 times a day for 7 days.

In addition to the above treatment, a systemic antibiotic injection, 2.0 mg/kg gentamycin sulphate (TROY Laboratories Limited Australia) intramuscularly once daily for a period of 4 days was added. Also, a non-steroidal anti-inflammatory drugs (NSAID) phenylbutazone (Vetoquinol France) at 4.4 mg/kg intravenously was administered once a day for 5 days. After the treatment, the penis was wrapped into the ventral abdominal wall by means of bandage (Figure 2) in order to avoid any accidental trauma to the pedunculated penis and to avoid the gravity effect which cause more fluid to get trapped in the lesion or swelling. Moreover, daily hand walking was recommended.



**Figure2. An illustration shown a horse penis bandaged to the ventral abdominal wall, a small open was made for urination. (artwork drawn and designed by the authors)**

The combination of local antiseptic solution, antibiotic ointment, systemic antibiotics and anti-inflammatory drugs, in addition to manual message gave satisfactory results. All the 3 cases were treated the same and the normal penile erectile function was restored.

## DISCUSSION

Paraphimosis is a critical problem for male horse as it interferes with the normal function of the penis and may lead to permanent penile damage. Swelling reduction should be main target of treatment, in addition to pain

relief. The earlier the intervention the better the prognosis for resorting penile function. Noninvasive granulomas and scar tissue or chronic inflammation that produces excessive thickening of the preputial tissue, which prevents retraction of the penis and lead to paraphimosis, such cases can be managed surgically either via circumcision or amputation of the penis depending on the extension of the lesion and the outcome of these surgical procedures are favorable (Turner et. al., 1982; Walker, and Vaughan, 1980). However, in case of traumatic lesions where hematoma and edematous fluid are the main cause of paraphimosis, a medical treatment including physical therapy and injections is indicated.

In this study the selection of potassium permanganate (PP) antiseptic solution was based on its astringent action that helps drying out blisters and prepare the wound for other treatments application. The PP solution was made by dissolving 15 gm of PP crystals in one litter of clean tap water. Potassium permanganate is an oxidizing agent with disinfectant and astringent properties. Potassium permanganate is commercially available as an odorless dark purple or almost black crystal or powder.

In terms of antibiotic ointment, Fucidin ointment (Sodium Fusidate Ph. Eur. 20 mg/g, Leo Laboratories Limited, UK) was applied because of its antibacterial properties. Fucidin ointment helps controlling infections and lubricating the area around the penis. In this study, the outcome of adjunctive therapies which includes NSAIDs of phenylbutazone and precautionary systemic antibiotic with gentamycin sulphate, an aminoglycoside antibiotic used for the treatment had improved the outcome and prevent secondary bacterial infections (Blanchard et al., 2003). Besides that, daily hand walking and manual massage shown similar observation out come as previous report (Brinsko et. al, 2007). The main target in treating paraphimosis cases is to reduce penile swelling as much as possible (Simmons et al., 1985). In addition, according to penile support (Blanchard et al, 2003) to prevent further swelling of the pendulous organ is imperative for a successful outcome. However, in this study, aggression behavior of one stallion would not allowed wrap the penis to the ventral abdominal wall and instead it is been left unwrapped and the animal was kept in complete rest to avoid any trauma to its penis. On the other hand, 2 stallions' penis were wrapped to the ventral abdominal wall (Figure 2) during the treatment and the outcome was favorable for both wrapped and unwrapped cases

The injection of antibiotics for 7 days along with non-steroidal anti-inflammatory drugs the hydrotherapy are very helpful adjuncts (Blanchard et. al., 2003). In addition, penile support to prevent further swelling of the pendulous organ is imperative for a successful outcome.

## CONCLUSION

The primary goal for successful treatment of paraphimosis is to reduce penile swelling to restore normal penile function and prevent further tissue damage. All 3 stallions returned to breeding activities and the owners were satisfied with the result.

## CONFLICT OF INTEREST

None of the authors have any potential conflicts of interest to declare. All authors are equally contributed to this work.

## ACKNOWLEDGEMENT

The author would like to thank the workers and technicians at the teaching hospital at the college of veterinary medicine at University of Tripoli .Tripoli-Libya for their assistance and taking care of the cases during re-habitation period.

## REFERENCES

- Blanchard, T.L., Varner, D.D. and Schumacher, J. (2003). Manual of Equine Reproduction, 2nd ed. St. Louis: Mosby.
- Brinsko, S.P., Blanchard, T. L., and Varner, D.D. (2007). How to treat paraphimosis in Proceedings of American Association of Equine Practitioners. 53: 580-582.
- Brinsko, S.P., Blanchard, T.L. and Varner, D.D. (2011). Surgery of the stallion reproductive tract. Manual of Equine Reproduction. 3<sup>rd</sup> ed. Maryland Heights, MO: Mosby Elsevier. Pp 242-75
- Henning, MW (1956). Animal diseases in south Africa, 3<sup>rd</sup> Ed, Pretoria, south Africa. Central News Agency Ltd.
- <https://www.dermnetnz.org/topics/potassium-permanganate/>
- <https://www.medicines.org.uk/emc/product/5513/smpe>
- Jörg, A. Auer, John A. Stick. (2012): Penis and Prepuce, Equine Surgery, 4<sup>th</sup> Ed, Saunders, United States. Pp 851.
- Memon, M.A., Usenik E.A. and Vamer, D.D.. (1988) penile paralysis and paraphimosis associated with reserpine administration in a stallion. Theriogenology. 30: 411- 419
- Neely, D.P. (1980). Physical examination and genital diseases of the stallion. in morrow. Current therapy in theriogenology. Philadelphia, W.B. Saunders
- Simmons, H.A., Cox, J.E. and Edwards, P.A. (1985). Paraphimosis in seven debilitated horses. Veterinary Record. 116:126-127.
- Turner, A.S., Mcil Wraith, C.M. (1982). techniques in large animal surgery. Philadelphia: Lea & Febiger .
- Walker , D.F. and Vaughan J.T. (1980) Bovine and equine urogenital surgery. Philadelphia: Lea & Febiger.