

PRIMARY TRANSMISSIBLE VENEREAL TUMOUR IN THE NASAL CAVITY OF TWO DOGS

M.M. Noordin, S. Jasni, M.L. Mohd-Azmi and A. Habibah

Faculty of Veterinary Medicine
Universiti Putra Malaysia, 43400 UPM Serdang, Selangor, Malaysia

SUMMARY

Transmissible venereal tumour (TVT) is a common tumour affecting dogs especially strays. Usually, the external genitalia is most frequently affected. Although there are reports of extra-genitalia TVT (usually secondary), incidence in the nasal cavity as a primary tumour is extremely rare. This paper describes the presence of primary TVT in the nasal cavity of two dogs along with the postulated pathogenesis. It also warrants clinicians to consider this tumour as one of the differentials for prolonged nasal discharge and nasal neoplasm.

Keywords: TVT, dogs, nasal cavity

INTRODUCTION

Roger (1997) documented that generally, the external genitalia of canines is most commonly affected by transmissible venereal tumour (TVT, Sticker's sarcoma). Ginel *et al.* (1995) reported a clinical case of TVT in the nasal cavity without affecting the external genitalia of a male dog.

This report describes similar cases in two male dogs at necropsy, which further supports the suggestion of including TVT as a differential in the diagnosis of nasal cavity neoplasm (Ginel *et al.*, 1995).

CASE HISTORY

The first case involved a four-year-old male mongrel which was presented at the UPM Veterinar teaching hospital with a complaint of bilateral mucopurulent nasal discharge. The dog was previously treated elsewhere without any improvement. After clinical examination, the dog was discharged after being prescribed with ampicillin (Penbritin; Becham), prednisolone (Delta-Cortef; Upjohn), bromhexine HCl (Bisolvon; Diethelm) and oxytetracycline HCl w/polymyxin B sulfate (Terramycin; Pfizer) eye ointment for seven days. A week later, the dog was hospitalised for further diagnosis. During hospitalisation, aminophylline (Neophylline; Fisons) was prescribed for twelve days while oral tetracycline and tetracycline ointment were prescribed for a week. β -haemolytic *Streptococcus sp.* and *Staphylococcus aureus* were isolated from the nasal cavity. Radiographic examination was not conducted and the dog was euthanised twelve days later.

The second case involved a 7-year-old Doberman cross that had a history of left unilateral epistaxis for almost two years as a result of trauma. The dog was hospitalised for one day for blood tests and bacterial culture. Results from both tests were inconclusive. The dog was later taken elsewhere and surgical intervention was performed. The

problem deteriorated leading to marked swelling of the nasal bridge and the left nares discharging mucopurulent exudate. It was brought back to our teaching Hospital for further examination. On physical examination, the upper hard palate was also found to be markedly swollen with the presence of whitish nodular masses on the hard palate. Radiography showed dense areas at the left nasal region with the sinuses also affected. The dog was discharged after being prescribed antibiotics and steroids for a week. The problem further deteriorated and the owner requested euthanasia.

POST MORTEM FINDINGS

In the first case, a severe mucopurulent conjunctivitis of both eyes was observed at necropsy. When the skull was cut longitudinally into two equal halves, a firm whitish sessile mass measuring approximately 4 cm in diameter that extended 1 cm towards the nasal cavity was seen (Figure 1). The external surface of this mass was cauliflower-like. Tenacious purulent exudate was also present in the frontal sinus. No significant lesions were seen in other systems.

The histological feature of the mass closely resembled that of TVT. The cells were uniformly ovoid with faint cytoplasm and were tightly packed with very minimal connective tissue stroma. In some areas, foci of fungus were seen (PAS stain). *Candida albicans* was isolated from the mass, nasal cavity and the frontal sinus.

Upon necropsy of the second case, a bilateral ulceration and purulent discharge of both medial canthi were evident. A bulge of approximately 5 cm in diameter was observed at the left nasal region. Almost the entire hard palate was replaced by a multilobulated whitish mass (Figure 2). This mass was also found to occupy the entire nasal cavity and extended to the subcutis of the left nares (Figure 2). However, there was no extension of the mass into the brain. No other lesions were seen elsewhere.

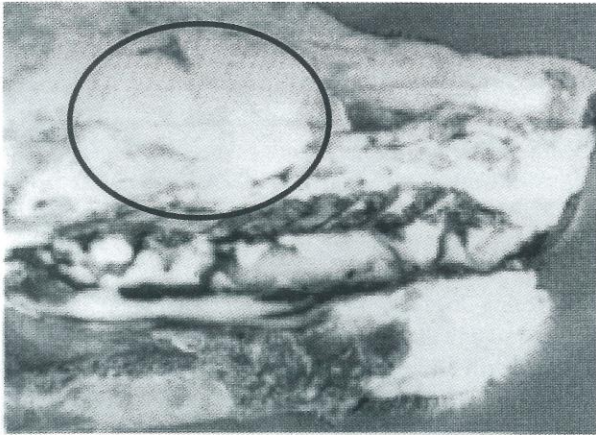


Fig. 1. Photograph of mongrel: a firm whitish sessile mass (encircled area) measuring approximately 4 cm in diameter that extended 1 cm towards the nasal cavity is seen in this cross section.

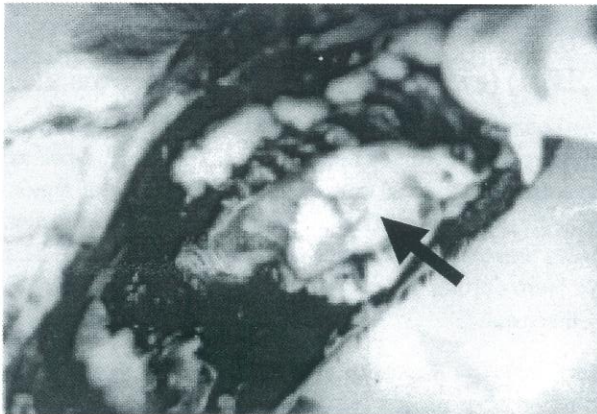


Fig. 2. Photograph of Doberman cross: the entire hard palate was replaced by multilobulated whitish mass (arrow) that occupied the entire nasal cavity and extended to the subcutis of the left nares.

Histologically, the mass was made up of almost uniform cells that were compactly arranged in a minimal connective tissue stroma (Figure 3). The cells mostly possessed ovoid nucleus with an indistinct cytoplasm. Mitotic figures and apoptosis were also present (Figure 3).

DISCUSSION

In our two cases, the clinical signs of epistaxis and mucopurulent discharge observed were consistent with those of nasal TVT (Brown *et al.*, 1980; Calvert *et al.*, 1982). However, the absence of tumour of the genitalia does support the suggestion that TVT should not be ruled out (Ginel *et al.*, 1995).

Higgins (1966) suggested that many of the skin sites where the tumour is found represent lesions of biting and scratching. We strongly believed that implantation of TVT in the nasal cavity of male dogs as described in this paper



Fig. 3. Photomicrograph of tumour from the nasal cavity of the mongrel. Note the presence of almost uniform cells, compactly arranged in a minimal connective tissue stroma. A number of cells are undergoing apoptosis (arrows) (H&E, X400).

is the result of sniffing TVT affected female genitalia prior to mating.

The implantation of viable tumour cells has been attributed to the breaching of intact tissues (Higgins, 1966). In the case reported here, history of trauma and mucopurulent discharge could indicate that damage of the tissue has occurred. However, it is still debatable as to whether the clinical signs seen were after the implantation of the tumour and that damage of the tissue is not a prerequisite for the implantation of TVT. This is further supported by the findings of Ginel *et al.* (1995) whereby evidence of injury to the tissue was absent or vague. Further studies should be carried out to verify the presence of injured tissue as a prerequisite for TVT implantation.

The significance of *Candida albicans* in one case could be associated with immunosuppression. The stress could be due to the effects of the steroids given or the presence of the tumour itself. This report warrants the need to include TVT as a differential in the diagnosis of prolonged nasal discharge and nasal cavity neoplasm.

REFERENCES

- Brown, N. O., Calvert, C. A. and Macewen, E. G. (1980). Chemotherapeutic management of transmissible venereal tumours in dogs. *J. Am. Vet. Med. Assoc.* **176**: 983-986.
- Calvert, C. A., Leifer, C. E. and Macewen, E. G. (1982). Vincristine for the treatment of transmissible venereal tumor in dogs. *J. Am. Vet. Med. Assoc.* **181**: 163-164.
- Higgins, D. A. (1966). Observation on the canine transmissible venereal tumour as seen in the Bahamas. *Vet. Rec.* **79**: 67-71.

- Ginel, P. J. Molleda, J. M., Novales, M., Martin, E., Margarito, J. M. and Lopez, R. (1995). Primary transmissible venereal tumour in the nasal cavity of a dog. *Vet. Rec.* **136**: 222-223.
- Roger, K. S. (1997). Transmissible venereal tumor. *The Compend.* **19**: 1036-1045.