

ATYPICAL MYCOTIC LESION IN THE GUTTURAL POUCH OF A THOROUGHBRED RACE HORSE

X.T. Yiew^{1*}, N.H. Khairuddin¹, A.I.K. Murdoch², P.V. Patil², R. Shashi Singam², C.P. Koay²

¹Faculty of Veterinary Medicine, Universiti Putra Malaysia, UPM Serdang, Selangor Darul Ehsan, Malaysia.

²Perak Turf Club Equine Hospital, Racecourse, Jalan Raja Di Hilir, Ipoh, Perak Darul Ridzuan, Malaysia.

SUMMARY

A six-year-old Thoroughbred race horse was presented with left unilateral mucopurulent nasal discharge. Endoscopic examination revealed atypical mycotic lesion within the guttural pouch in which the fungal mass was not located on any neurovascular structures. This case was successfully treated by the combination of manual debulking of fungal diphtheritic plaques and medical treatment that included daily local irrigation and systemic medication. There were no complications and the horse returned to race three weeks later.

Keywords: Atypical, guttural pouch; manual debulking; medical treatment; mycosi

INTRODUCTION

Guttural pouch mycosis is a fungal infection within the guttural pouches that disrupt the integrity of surrounding neurovascular supply, leading to severe haemorrhage and neurological deficits. In horses, mycosis of the guttural pouch is considered a rare and opportunistic life threatening infection with no particular age, breed, or sex predisposition (Ludwig *et al.*, 2005; Cook, 1966).

The common location of diphtheritic fungal plaques is the caudodorsal region of the guttural pouch, medial to the articular junction of the hyoid and petrous temporal bones (Cook, 1966; Cook, 1968). Typically fungal growth would spread extensively to involve vital structures within the pouch such as the internal carotid artery, cranial nerves IX, X, XII, and VII, the sympathetic trunk and the stylohyoid bone. In more advanced stages, it could extend forward to the pharyngeal recess (Greet, 1987), laterally to the lateral compartment, or medially to the contralateral guttural pouch (Jacobs and Fretz, 1982). Until this day, it is still unclear why specific anatomical areas are invaded and what are the predisposing factors for their development. However there have been several case reports on atypical locations in which the fungal plaque was not situated on any major blood vessels within the guttural pouch (Lane and Mair, 1987; Carmalt and Baptiste, 2004).

The most common fungus to invade the guttural pouch is *Aspergillus spp.*, principally *A. Nidulans* (Johnson *et al.*, 1973; Rawlinson and Jones, 1978), *A. Fumigatus* (Guillot *et al.*, 1997), *A. Ochraceus* (Gresti *et al.*, 1993), and *A. flavus*. *Aspergillus spp.* are opportunistic fungi present in normal equine airways, soil and decaying vegetation or animal waste however it usually requires an immune-suppressed or debilitated host to establish infection under normal circumstances (Lepage *et al.*, 2004).

Medical management which is said to be expensive, have lower success rate and much slower response to topical treatment has long been phased out by the ever evolving surgical intervention. Over the years, surgical

Phone No.: +6012 3731845; Email: yiewxiuting@gmail.com

treatment has evolved from surgical ligation (Johnson *et al.*, 1973; Owen, 1974), to balloon-tipped catheter transarterial occlusion (Freeman and Donawick, 1980a; Freeman and Donawick, 1980b), followed by modification to the use of detachable, self-sealing intravascular balloons (Cheramie *et al.*, 1999), transarterial coil embolisation (Léveillé *et al.*, 2000), and more recently the development of surgical occlusion techniques in standing horses (Marcus *et al.*, 2005; Benredouane and Lepage, 2012).

This case report describes an atypical case of guttural pouch mycosis in which the fungal plaque was not located on any neurovascular structures. A combination of manual debulking and medical treatment were carried out with successful outcome.

CASE REPORT

A six-year-old, 500 kg Thoroughbred gelding used for flat racing was presented to the Perak Turf Club Equine Hospital with the primary complaint of copious mucopurulent nasal discharge which started a few days prior to presentation. The gelding's appetite, bowel, and urination were normal and no coughing was reported. Vaccination and deworming history were current.

Upon physical examination, the gelding was bright, alert, and responsive with unilateral mucopurulent nasal discharge observed from the left nostril (Figure 1). Other vital parameters were within normal range and no other abnormalities were found.

Nasal discharge sample was collected using a sterile swab and upon Gram staining revealed many gram negative rods while bacterial culture resulted in moderate growth of *Klebsiella sp.* that is resistant to amoxicillin-clavulanic acid, trimethoprim-sulfamethoxazole, and cefuroxime.

Endoscopic examination of the upper respiratory tract was also performed using a videoendoscope (Pentax 3.8 EC-3470FK scope attached to Pentax EPK-1000) under light sedation using a combination of 0.02 mg/kg acepromazine (Calmivet Solution Injectable 5 mg/mL, Vétoquinol, France) and 0.5 mg/kg xylazine (Ilium Xylazil 100 mg/mL, Troy Laboratories Pty Ltd,

*Corresponding Author: Dr.Yiew Xiu Ting (X.T. Yiew);

Australia). The upper respiratory tract structures were found to be normal with the exception of thick green-yellow mucopurulent exudate oozing from the left nasopharyngeal opening.

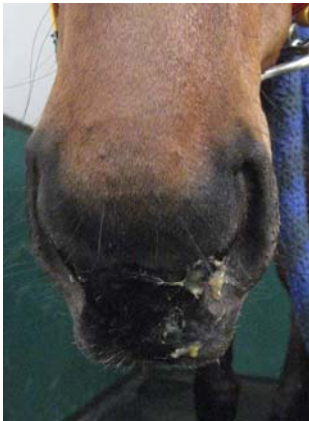

Figure 1. Gelding presented with left unilateral mucopurulent nasal discharge

As the endoscope was advanced into the left guttural pouch, whitish diphtheritic fungal plaque was found on the roof of the pouch, mainly covering the mucosal surface overlying the stylohyoid bone (Figure 2). In this case, the fungal mass was localized to the dorsal region of the stylohyoid bone and has not extended to the internal, external, or maxillary arteries. Based on the endoscopic visualisation of characteristic lesion, the definitive diagnosis of atypical guttural pouch mycosis without invasion of neurovascular structures was made.

As the fungal mass did not involve any blood vessels, manually debulking of the fungal plaques was

attempted. A transendoscopic biopsy and grasping forcep was passed through the biopsy channel of the videoendoscope and was used to gently detach the diphtheritic fungal plaques, carefully avoiding the important structures such as blood vessels and nerves (Figure 2).

The affected guttural pouch was then lavaged profusely with 1 L of 0.003% (v/v) povidone iodine solution (U-Iodin Lotion, 1% available iodine, Malaysian Pharmaceutical Industries Sdn. Bhd., Malaysia) followed by 30 mL of fluconazole (Diflucan I.V. 2 mg/mL, Pfizer, United States of America). This local guttural pouch irrigation was repeated on a daily basis for a total duration of 3 weeks.

In addition to the daily guttural pouch lavage, the gelding was treated medically with 120 mL sodium iodide (Sodium Iodide 20% Solution, Univet Pharmaceuticals Ltd., Canada) intravenously once daily and benzyl penicillin 10 mg/kg (Mamyzin 333.3 mg/mL, Boehringer Ingelheim, Berkshire) intramuscularly once daily for 5 days. Sodium iodide was discontinued after 5 days as the horse started to show signs of iodism such as excessive lacrimation. Once the bacteriology culture and antibiotic sensitivity result was obtained, benzyl penicillin was changed to enrofloxacin 5 mg/kg (TavetEnrofloxacin 5%, TavVeterinaria S. L., SantMartí de Centelles, Spain) intravenously once daily for an additional duration of 2 weeks.

Post treatment, a significant improvements were observed in terms of clinical signs and endoscopic findings from day 2 until day 8 of treatment (Figure 3). The guttural pouch mycosis resolved completely over 3 weeks and the horse returned to race.

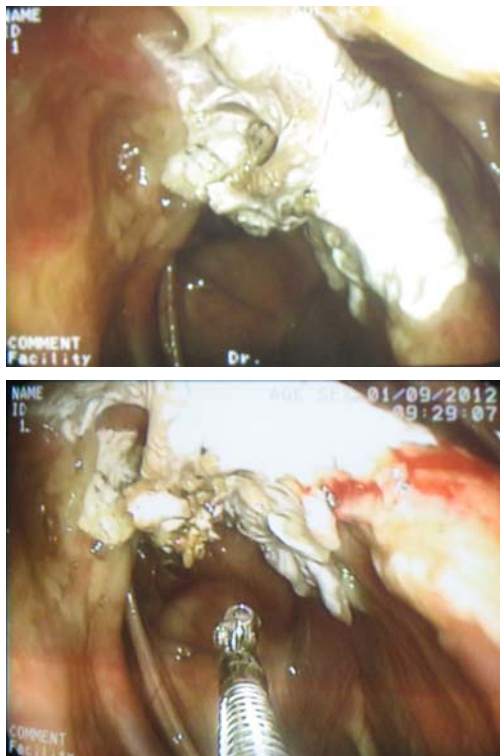


Figure 2. (Top) Endoscopic appearance and location of diphtheritic fungal plaque within the left guttural pouch; (Bottom) Manual debulking of fungal plaques using a transendoscopic biopsy and grasping forceps

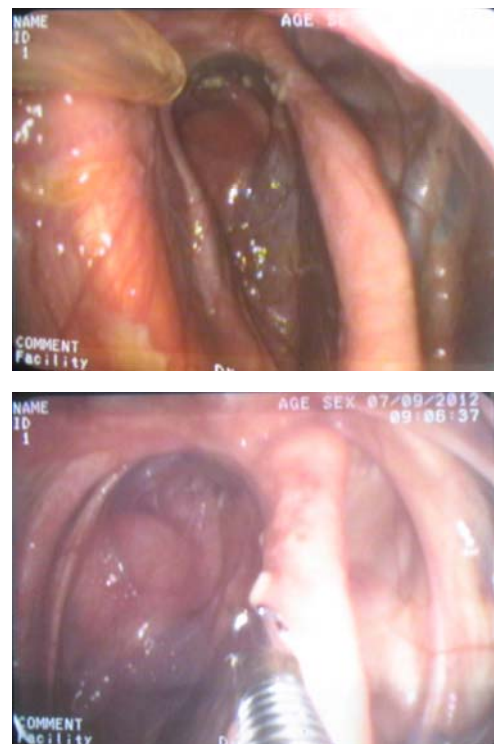


Figure 3: (Top) Endoscopic findings on day 5 post treatment; (Bottom) Endoscopic findings on day 8 post treatment

DISCUSSION

The gelding in this case did not demonstrate typical signs of guttural pouch mycosis such as epistaxis or neurological disorders (Cook, 1966; Greet, 1987). The only presenting sign was copious thick unilateral mucopurulent nasal discharge believed to be a result of concurrent empyema which most likely occurred secondary to the fungal infection (Cook, 1968; Lepage *et al.*, 2004). There was no episode of epistaxis experienced by this gelding as the fungal infection was diagnosed early before the lesion extended to the major vessels within the guttural pouch. Being an active race horse, this particular gelding was stabled in a box and was handled frequently thereby allowing early detection and prompt treatment of the infection.

The diagnosis of atypical guttural pouch mycosis in this case was made based on history, clinical signs and the endoscopic visualisation of plaque-like diphtheritic membrane or mass within the guttural pouch. With endoscopes widely available now, guttural pouches has become a routine part of upper respiratory tract examination and abnormalities are observed more frequently without obvious pathognomonic clinical signs (Baptiste, 2004). In this case, biopsy for fungal culture or histopathological examination was not performed as it is not necessary for diagnosis but could be performed for epidemiological purposes (Lepage *et al.*, 2004).

The exact pathogenesis of guttural pouch mycosis still remains a mystery although aetiologies such as secretory otitis, thrombo-arteritis and arterial aneurysm had been proposed (Cook, 1968; Cook *et al.*, 1968). In this case, it is suggested that this gelding could have contracted the fungal infection via inhalation of dirt kicked up from the turf track. When the horse swallows, the pharyngeal orifices open allowing opportunity for dirt and soil particle to enter the guttural pouch. In addition to that, the lack of light, warmth, humidity, and poor ventilation could provide a suitable environment for the fungus to proliferate (Cook, 1968).

Guttural pouch mycosis can be treated medically or surgically depending on the situation. Medical treatment may be attempted in cases where there is no probable risk of haemorrhage; however if a fungal lesion is located on an artery, surgical occlusion of the affected blood vessel is strongly recommended.

Considering that medical treatment alone would take a long time for the fungal plaque to resolve and would require huge commitment from the trainer to follow up with the long treatment duration, careful debridement was considered in hope for quicker remission and better contact of topical antifungal solution as the organisms are well protected within superficial layer of necrotic tissue and fibrin (Church *et al.*, 1986; Freeman, 1990; Freeman, 1991). With no epistaxis and no major vessels involvement, judicious decision was made to combine surgical removal of fungal plaques via manual debulking and medical treatment. Many has discouraged the choice of manual debulking as it is said to be dangerous and can precipitate fatal haemorrhage or severe cranial nerve deficits (Johnson *et al.*, 1973; Church *et al.*, 1986; Rush and Mair, 2004). However careful debridement of the

fungal plaques and necrotic tissues is believed to have contributed to faster remission and the successful outcome of this case.

Fluconazole was used in this case instead of nystatin powder or enilconazole due to drug availability. Perhaps the outcome of this case could be even better if nystatin powder or enilconazole is used as they are reported to be able to ensure prolonged contact to the fungal plaque (Carmalt and Baptiste, 2004; Church *et al.*, 1986).

Although in many instances surgical occlusion of the invaded artery results in the disappearance of fungal plaques, most of them require general anaesthesia as well as large, specialized, and expensive equipment and is not without their own risks (Baptiste, 2004). A method of occlusion in standing horses which involves transendoscopic application of a clip has been described; however this technique is only applicable for small vessels due to the small diameter of commercial clips (Markus *et al.*, 2005). More recently, a modified transarterial coil embolisation technique in standing horses was reported to be safe, minimally invasive and effective yet it requires the use of fluoroscopy which is not available in the hospital (Benredouane and Lepage, 2012). Therefore after careful consideration of various aspects, daily endoscopic evaluation with careful debridement and guttural pouch lavage in combination with parenteral medical treatment was the preferred option since the fungal infection was still in its early stage.

CONCLUSIONS

In conclusion, the combination therapy chosen in this case proved to be effective and successful with persistent and close monitoring.

FUNDING

The authors received no specific grant from any funding agency in the public, commercial or not-for-profit sectors for the preparation of this case report.

CONFLICT OF INTEREST

None of the authors of this paper has any financial or personal relationship with other people or organisations that could inappropriately influence or bias the content of the paper.

REFERENCES

- Baptiste, K.E. (2004). The mystery of guttural pouch mycosis: the paradox of advancing knowledge of a rare disease. *The Veterinary Journal* 168:1-2.
- Benredouane, K., and Lepage, O.M. (2012). Trans-arterial coil embolization of the internal carotid artery in standing horses. *Veterinary Surgery* 41:404-409.
- Carmalt, J.L., and Baptiste, K.E. (2004). Atypical guttural pouch mycosis in three horses. *Pferdeheilkunde* 20, 542-548.
- Cheremie, H.S., Pleasant, R.S., Robertson, J.L., Moll, H.D., Carrig, C.B., Freeman, D.E., and Jensen, M.E. (1999). Evaluation of a technique to occlude the internal carotid artery of horses. *Veterinary Surgery* 28: 83-90.
- Church, S., Wyn-Jones, G., Parks, A.H., and Ritchie, H.E. (1986). Treatment of guttural pouch mycosis. *Equine Veterinary Journal* 18: 362-365.

- Cook, W.R. (1966). Observations on the aetiology of epistaxis and cranial nerve paralysis in the horse. *Veterinary Records* 78: 396-405.
- Cook, W.R. (1968). Clinical features of guttural pouch mycosis in the horse. *Veterinary Record*. 83: 336-345.
- Cook, W.R., Campbell, R.S.F., and Dawson, C. (1968). Pathology and aetiology of guttural pouch mycosis. *Veterinary Record*. 83: 422-428.
- Freeman, D.E. and Donawick, W.J. (1989a). Occlusion of the internal carotid artery in the horse by means of a balloon-tipped catheter: evaluation of a method designed to prevent epistaxis caused by guttural pouch mycosis. *Journal of American Veterinary Medical Association*. 176: 232-235.
- Freeman, D.E., and Donawick, W.J. (1980b). Occlusion of the internal carotid artery of the horse by means of a balloon-tipped catheter: clinical use of a method to prevent epistaxis caused by guttural pouch mycosis. *Journal of American Veterinary Medical Association* 176: 236-240.
- Freeman, D.E. (1990): Guttural pouches. In: *Current Practice of Equine Surgery*. White, N.A., and Moore, J.N.(Ed.), J.B. Lippincott Company, Philadelphia. pp. 240-251.
- Freeman, D.E. (1991); Guttural pouches. In: *Equine Respiratory Disorders*. Beech, J., Lea, and Febiger(Ed.), London. pp. 305-330.
- Greet, T.R.C. (1987). Outcome of treatment in 35 cases of guttural pouch mycosis. *Equine Veterinary Journal*. 19: 483-487.
- Gresti, de A., Barone, P., and Perniola, N. (1993). Un caso di micosidelle tasche gutturali causato da *Aspergillus ochraceus*: diagnosi e terapia [A case of guttural pouch mycosis caused by *Aspergillus ochraceus*: diagnosis and therapy]. *Ippologia* 4: 81-86.
- Guillot, J., Sarfati, J., Ribot, X., Jensen, H.E., and Latgé, J.P. (1997). Detection of antibodies to *Aspergillus fumigatus* in serum of horses with mycosis of the auditory tube diverticulum (guttural pouch). *American Journal of Veterinary Research*. 58: 1364.
- Jacobs, K.A., and Fretz, P.B. (1982). Fistula between the guttural pouches and the dorsal pharyngeal recess as a sequel to guttural pouch mycosis in the horse. *Canadian Veterinary Journal*. 23: 117-118.
- Johnson, J.H., Merriam, J.G., and Attleberger, M. (1973). A case of guttural pouch mycosis caused by *Aspergillus nidulans*. *Veterinary Medicine and Small Animal Clinician*. 68: 771-774.
- Lane, J.G., and Mair, T.S. (1987). Observations on headshaking in the horse. *Equine Vet Journal*. 19: 331-336.
- Lepage, O.M., Perron, M.F., and Cadoré, J.L. (2004). The mystery of fungal infection in the guttural pouches. *Veterinary Journal*. 168: 60-64.
- Léveillé, R., Hardy, J., Robertson, J.T., Willis, A.M., Beard, W.L., Weisbrode, S.E., and Lepage, O.M. (2000). Transarterial coil embolization of the internal and external carotid and maxillary arteries for prevention of haemorrhage from guttural pouch mycosis in horses. *Veterinary Surgeon*. 29: 389-397.
- Ludwig, A., Gatineau, S., Reynaud, M.C., Cadoré, J.L., and Bourdoiseau, G. (2005). Fungal isolation and identification in 21 cases of guttural pouch mycosis in horses (1998-2002). *Veterinary Journal* 169: 457-461.
- Markus, R., Deegen, E., and Drommer, W. (2005). Guttural pouch mycosis. *Journal of Equine Veterinary Science*. 25: 150-156.
- Owen, R. (1974). Epistaxis prevented by ligation of the internal carotid artery in the guttural pouch. *Equine Veterinary Journal*. 6: 143-149.
- Rawlinson, R.J., and Jones, R.T. (1978). Guttural pouch mycosis in two horses. *Australian Veterinary Journal*. 54: 135-138.
- Rush, B., and Mair, T.S. (2004): The guttural pouches. In: *Equine Respiratory Diseases*. Rush, B. and Mair, T.S. (Ed.), 1st. ed., Blackwell, Oxford. Pp. 57-80