

## THE EFFECT OF TOPICAL APPLICATION OF MALAYSIAN HONEY ON BURN WOUND HEALING

M.Z. Rozaini<sup>1</sup>, A.B.Z. Zuki<sup>1</sup>, M. M. Noordin<sup>1</sup>, Y. Norimah<sup>2</sup> and A. Nazrul Hakim<sup>3</sup>

<sup>1</sup>Faculty of Veterinary Medicine, <sup>3</sup>Faculty of Medicine and Health Sciences,  
Universiti Putra Malaysia 43400 UPM, Serdang, Selangor, Malaysia.

<sup>2</sup>Malaysian Institute for Nuclear Technology for Research (MINT) Bangi,  
43000 Kajang, Selangor, Malaysia.

### SUMMARY

The efficacy of topical application of Malaysian honey on burn wound healing in Sprague-Dawley rats was investigated using 45 Sprague Dawley male rats weighing 200-300 g. Deep partial skin thickness burns were inflicted on the dorsal part of each animal. Two types of local honey (durian and Gelam) were applied twice a day in a quantity of 0.5 ml for each application, while control animals received no treatment. The rats were serially euthanised at 3, 7, 14, 21 and 28 days post treatment for histological study. Histologically, early attenuation of inflammatory reaction and early reparative activities were observed in the honey treated wounds compared to control groups. Differential cells count showed a significant decreased in the number of inflammatory cells and increased vascularity in the honey treated wounds as early as 3 days post injury. In addition, epithelial regeneration appeared to be significant in gelam honey treated wound. This study showed that there was a significant acceleration of dermal repair in wound healing treated with durian and Gelam honey.

Keywords: burn wound, honey, rats

### INTRODUCTION

Burn wound is a dynamic wound that can deepen in time, thereby increasing the total tissue damage and is prone to infection (Middelkoop *et al.*, 2003). Many of the synthetic drugs to treat burn wounds are rather expensive and pose problems such as allergy, as well as adverse drugs effects forcing scientists all over the world to seek for an alternative treatment (Edwards-Jones and Greenwood, 2003).

Naturally occurring substances such as honey which are easily available, cheap and non-toxic have been found to be useful to treat burn wound (Subrahmanyam, 1996). Ironically, honey has been used as a medicine for thousand of years and its curative properties are well documented (Molan, 1999). Interest in honey as a wound healing promoter has been rekindled in the scientific community. Its efficacy in wound healing remains largely anecdotal with claims that it reduces inflammation, debrides necrotic tissue, reduces oedema and promotes angiogenesis, granulation and epithelialisation (Molan, 1998). The healing properties of honey also vary due to the source of nectar as well as climate which affect the composition of honey (Aljady *et al.*, 2000).

The present study was designed to evaluate the wound healing potential of two selected Malaysian local honey in the management of burn wound by evaluating the histological changes.

### MATERIALS AND METHODS

#### Honey samples

Local *Apis cerana* honeys were used from the floral sources of durian (*Durio zibethinus spp.*) and Gelam (*Melaleuca spp.*) trees. The honeys were sterilised by gamma-irradiation (25 kGy).

#### Animal models

A total of 45 male Sprague-Dawley rats weighing 200-300g were used in this study. Each animal was kept in individual cages and given commercial pellet and water *ad libitum* throughout the study.

#### Preparation of the skin

The rats were anaesthetised with an intramuscular injection of Ketamine (50mg/kg) and xylazine (5mg/kg). Following anaesthesia, the back and flanks of both sides were clipped and shaved using razor blade. Since shaving procedure produced marked oedema of the skin, the prepared rats were left for twenty-four hours before the burn was inflicted.

#### Burn infliction

Deep partial skin thickness burn was inflicted on the dorsum of the rat's body using a cylindrical stainless steel template heated in a water bath at a constant temperature

of 85°C, using a modification of a previously described method (Kaufman *et al.*, 1990).

#### *Grouping and mode of treatment*

Animals were divided into three groups comprising 15 rats each. Topical application of honey and a thin layer of SSD cream was administered twice a day on the burn wounds while the control group did not receive any treatment. For each group, three animals were sacrificed on the 3<sup>rd</sup>, 7<sup>th</sup>, 14<sup>th</sup>, 21<sup>st</sup> and 28<sup>th</sup> day post wounding. All samples were subjected to standard Haematoxylin and Eosin (H&E) staining.

#### *Histological assessment*

After general histologic examination, differential cell counts were carried out on the sections using a 0.01mm graticule to assess the following cells, namely: neutrophils, macrophages, fibroblasts and endothelial cells (Dyson *et al.*, 1988).

#### *Statistical analysis*

Data obtained were analysed using a two-way ANOVA. Data were considered significant at  $P < 0.05$ .

## **RESULTS**

The results of differential cell counts are shown in Table 1. There were significantly ( $p < 0.05$ ) less inflammatory cells (neutrophils and macrophages) and higher cells count of proliferative cells (fibroblasts and endothelial cells) observed in honey treated wounds by day 3 post injury. After 7 days post burned, Gelam honey treated groups showed a significantly lower neutrophils and significantly higher number of fibroblasts compared to durian honey and control groups ( $p < 0.05$ ). The granulation tissue of gelam (Fig.1c) and durian honey treated wounds (Fig.1b) were better vascularised while epithelial regeneration appeared to be quite advanced in wound treated with Gelam honey (Fig.1c). Contrary to the control wounds (Fig.1a), the granulation tissue consisted of marked inflammatory cells and poor vascularisation.

By day 14, the inflammatory cells remained significantly ( $p < 0.05$ ) higher in the control animals with relatively lower counts of proliferative cells in comparison with honey treated wounds. The number of endothelial cells were significantly ( $p < 0.05$ ) higher in honey treated groups by day 21 while fibroblasts cell count started to decrease significantly in wound treated with Gelam honey ( $p < 0.05$ ). After 28 days post injury, honey treated wounds exhibited significantly ( $p < 0.05$ ) lower inflammatory cells compared to untreated control group. Durian honey

treated wound showed a significant decrease in the number of fibroblasts ( $p < 0.05$ ) with relatively higher counts of endothelial cells.

## **DISCUSSION**

Wound healing is a complex event involving a number of well-orchestrated processes which are characterised by three important stages consisting of the inflammatory, proliferative and remodeling phases. The present study showed that honey reduced the number of polymorphonuclear leukocytes involved in the inflammation stage. Thus, it could be inferred that honey has an anti-inflammatory effect on healing wounds. The observation that by day 3 post-burned, there were significantly less inflammatory cells in wounds of honey treated rats suggest that the inflammatory phase was less intense. The decrease in neutrophils and increase in fibroblast and endothelial cells in the honey treated wounds by day 7 post burned suggests that healing was well advanced into proliferative phase from the initial inflammatory stage (Dyson *et al.*, 1988). Early regeneration appeared to be quite advanced in the treatment groups of gelam honey by day 7 post-burned. Moist ambience provided by honey due to its high viscosity is the best suited condition for wound epithelisation (Molan, 2001). Aljady *et al.* (2000) have also reported fibroblasts stimulation and increased epithelisation by local honey on the basis of biochemical changes. Topical acidification has been shown to promote healing (Kaufman *et al.*, 1984) and the pH of honey is known to help create and maintain optimal conditions for fibroblast activity (Lusby *et al.*, 2002).

The decrease in fibroblasts marks the end of repair stage of healing and the beginning of the remodeling phase (Dyson *et al.*, 1988). With fewer fibroblasts, collagen synthesis decreases until it equilibrates with the rate of destruction (Swaim, 1997). The significant fall in the number of fibroblasts in Gelam honey treated wounds by day 21 post injury suggest a more rapid progress through the remodeling phase.

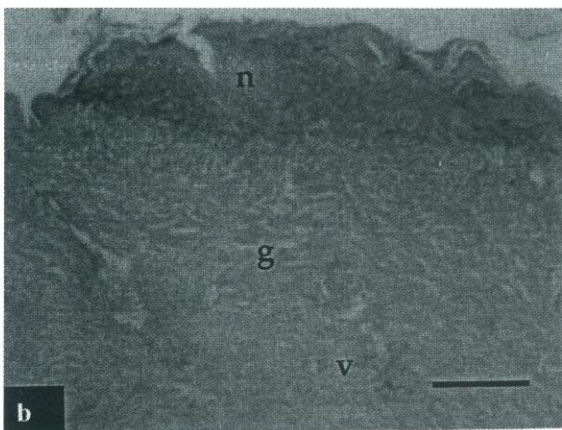
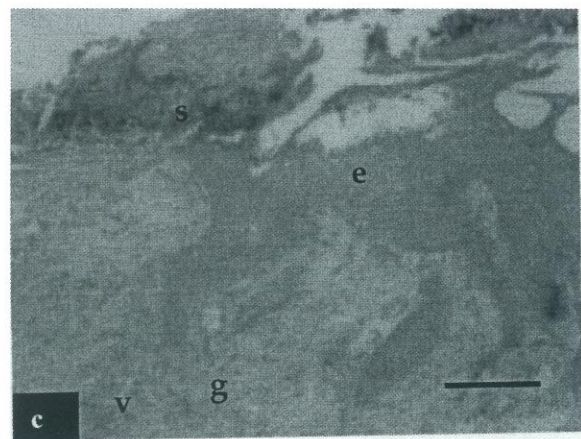
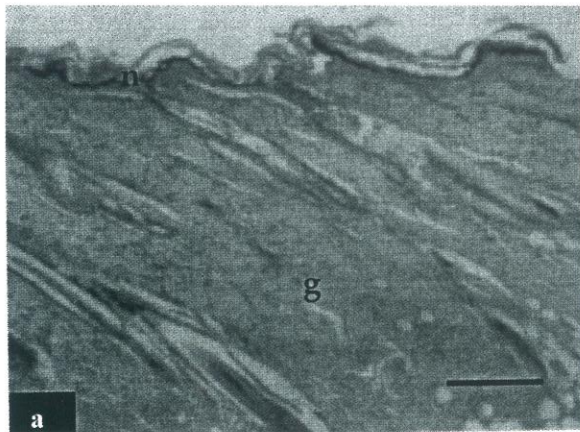
The results obtained from this research indicate that Gelam honey and durian honey modulate wound inflammation and neovascularisation as well as stimulate fibroblasts formation. In addition, enhanced re-epithelisation was also observed gelam honey treated wounds. In conclusion, this study showed that our local honey may play a positive role in burn wound management. Nevertheless, as this result needs a detailed appraisal, an *in-vitro* study should be carried out to substantiate the present findings.

**Table 1: The cell counts in the skin wound at various intervals ( mean  $\pm$  S.D)**

Cell	Groups	Intervals (Days post burned)				
		3	7	14	21	28
Neutrophils	Control	164.80 $\pm$ 26.0 <sup>c,y</sup>	241.00 $\pm$ 43.3 <sup>c,z</sup>	93.06 $\pm$ 26.5 <sup>b,x</sup>	6.43 $\pm$ 3.8 <sup>ab,w</sup>	3.06 $\pm$ 1.0 <sup>b,w</sup>
	Durian	105.40 $\pm$ 29.0 <sup>b,y</sup>	68.66 $\pm$ 9.6 <sup>b,x</sup>	11.50 $\pm$ 2.6 <sup>a,w</sup>	11.56 $\pm$ 7.2 <sup>b,w</sup>	1.00 $\pm$ 0.2 <sup>a,w</sup>
	Gelam	67.46 $\pm$ 5.4 <sup>a,y</sup>	26.50 $\pm$ 5.8 <sup>a,x</sup>	6.86 $\pm$ 1.3 <sup>a</sup>	3.93 $\pm$ 5.3 <sup>a,w</sup>	0.40 $\pm$ 0.3 <sup>a,w</sup>
Macrophages	Control	41.53 $\pm$ 12.4 <sup>b,y</sup>	65.66 $\pm$ 9.0 <sup>b,z</sup>	32.30 $\pm$ 3.6 <sup>b,xy</sup>	22.0 $\pm$ 4.0 <sup>b,wx</sup>	12.06 $\pm$ 2.3 <sup>b,w</sup>
	Durian	24.66 $\pm$ 4.6 <sup>a,y</sup>	25.7 $\pm$ 2.4 <sup>a,y</sup>	14.03 $\pm$ 1.8 <sup>a,x</sup>	16.66 $\pm$ 3.4 <sup>b,x</sup>	1.90 $\pm$ 0.3 <sup>a,w</sup>
	Gelam	28.93 $\pm$ 5.5 <sup>a,y</sup>	27.36 $\pm$ 8.4 <sup>a,y</sup>	10.0 $\pm$ 2.6 <sup>a,x</sup>	1.0 $\pm$ 0.2 <sup>a,w</sup>	0.8 $\pm$ 0.1 <sup>a,w</sup>
Fibroblasts	Control	23.50 $\pm$ 14.0 <sup>a,w</sup>	40.90 $\pm$ 4.4 <sup>a,x</sup>	47.06 $\pm$ 4.9 <sup>a,xy</sup>	60.63 $\pm$ 5.5 <sup>b,y</sup>	51.43 $\pm$ 3.7 <sup>c,xy</sup>
	Durian	33.90 $\pm$ 4.5 <sup>ab,w</sup>	46.76 $\pm$ 3.3 <sup>a,x</sup>	50.43 $\pm$ 2.1 <sup>a,x</sup>	69.16 $\pm$ 4.2 <sup>b,y</sup>	46.13 $\pm$ 5.1 <sup>bc,x</sup>
	Gelam	44.56 $\pm$ 4.1 <sup>b,x</sup>	56.86 $\pm$ 6.8 <sup>b,y</sup>	68.26 $\pm$ 9.1 <sup>b,y</sup>	49.23 $\pm$ 5.6 <sup>a,x</sup>	27.30 $\pm$ 6.6 <sup>a,w</sup>
Endothelial	Control	2.63 $\pm$ 1.0 <sup>a,w</sup>	4.36 $\pm$ 0.7 <sup>a,x</sup>	3.33 $\pm$ 1.2 <sup>a,wx</sup>	3.86 $\pm$ 0.3 <sup>a,wx</sup>	4.30 $\pm$ 0.6 <sup>a,wx</sup>
	Durian	7.46 $\pm$ 2.2 <sup>c,x</sup>	10.60 $\pm$ 1.5 <sup>c,y</sup>	3.73 $\pm$ 0.8 <sup>a,w</sup>	8.33 $\pm$ 0.5 <sup>b,xy</sup>	6.66 $\pm$ 0.6 <sup>b,x</sup>
	Gelam	5.76 $\pm$ 0.8 <sup>bc,w</sup>	6.90 $\pm$ 0.6 <sup>b,xy</sup>	6.56 $\pm$ 0.6 <sup>b,wx</sup>	7.20 $\pm$ 0.5 <sup>b,y</sup>	5.40 $\pm$ 0.6 <sup>a,w</sup>

<sup>a,b,c</sup>Means with different superscripts within a column were significantly different at  $p < 0.05$ .

<sup>x,y,z</sup>Means with different superscripts within a row were significantly different at  $p < 0.05$ .



**Fig. 1.** Photomicrograph of wound sections at day 7 post-burned stained with H&E. (a) untreated control group, (b) durian honey treated wounds, and (c) Gelam honey treated wounds. Note the epidermal regeneration in Gelam honey treated wound under scab formation. Necrotic debris still present on the superficial layer of dermis in control and durian honey treated wounds. Bars on the photomicrograph represent 20 $\mu$ m. e: epidermis; g: granulation tissue; n: necrotic debris.

## REFERENCES

- Aljady, A.M., Kamaruddin, M.Y., Jamal, A.M and Mohd. Yassim M.Y. (2000). Biochemical study on the efficacy of Malaysian honey on inflicted wounds : an animal model. *Medical Journal of Islamic Academy of Sciences* **13**: 125-132.

- Dyson, M, Young, SR, Pendle, L, Webster, DF, Lang, S. (1988). Comparison of the effects of moist and dry conditions on dermal repair. *J. Invest Dermatol.* **91**: 434-439.
- Edward-Jones, V. and Greenwood, J.E. (2003). What's new in burn microbiology? James Laing Memorial Prize Essay 2000. *Burns* **29**: 15-24.
- Kaufman, T., Lusthaus, S.N., Sagher, U. and Wexler, M. R. (1990). Deep partial skin thickness burns: a reproducible animal model to study burn wound healing. *Burns* **16**: 13-16.
- Kaufman, T., Levin, M. and Hurwitz, D.J. (1984). The effect of topical hyperalimantation on wound healing rate and granulation tissue formation of experimental deep second degree burns in guinea-pigs. *Burns* **10**: 252-256.
- Lusby, P.E., Coombes, A. and Wilkinson, J.M. (2002). Honey: A potent agent for wound healing? *Journal of Wound, Ostomy and Continence Nurses Society* **29**: 295-300.
- Molan, P.C. (1998). The evidence for honey promoting wound healing. *Primary Intention The Australian Journal of Wound Management.* **6**: 148-158.
- Molan, P.C. (1999). Why honey is effective as a medicine. I. its use in modern medicine. *Bee World* **80**: 80-92.
- Molan, P.C. (2001). Potential of honey in the treatment of wounds and burns. *Am. J of Clin. Derm.* **2**: 13-19.
- Middelkoop, E., Van de Bogaerdt, A. J., Lamme, E.N., Hoekstra, M.J., Brandsma, K. and Ulrich, M.M.W. (2003). Porcine wound models for skin substitution and burn treatment. *Biomaterials* **25**: 1559-1567.
- Subrahmanyam, M. (1996). Honey dressing versus boiled potato peel in the treatment of burns: a prospective randomized study. *Burns* **22**: 491-493.
- Swaim, S.F. Henderson, R.A. 1997. *Small Animal Wound Management.* 2<sup>nd</sup> ed. Maryland, Williams and Wilkins.