J. Vet. Malaysia (1990) 2(1): 47-49

SHORT COMMUNICATION

A CASE OF HEPATIC COCCIDIOSIS IN RABBIT

SUMMARY: A case of hepatic coccidiosis in two young rabbits is described. Characteristic lesions of hepatic coccidiosis in the liver were observed grossly and under histopathology.

Key words: coccidiosis, liver, rabbit

INTRODUCTION

Rabbit farming is growing rapidly in Malaysia and one of the important diseases of rabbit is coccidiosis. There are two forms of this disease: hepatic caused by *Eimeria stiedai*, and intestinal, the cause of which may be *E. magma*, *E. irresidua*, *E. media* or *E. perforans* (Soulsby, 1982). Transmission of both forms is by ingestion of sporulated oocysts in contaminated feed and water. Coccidiosis usually affects young rabbits and is seen especially in breeding and rearing establishments where sanitation is poor (Soulsby, 1982).

This paper reports a case of hepatic coccidiosis in rabbit based on gross and histopathological examinations of the liver tissues.

MATERIALS AND METHODS

Two sets of organs in ice and 10 percent neutral buffered formalin from two one-month-old rabbits were sent to us from a pet shop in Dungun, Trengganu. These two rabbits were observed to show signs of diarrhoea, listlessness and a slight distension of the abdomen before death.

The two sets of specimen were subjected to parasitological, bacteriological and histopathological examinations.

RESULTS AND DISCUSSION

Gross examination of the specimen showed the liver filled with pus-like materials, with generalised yellowish white depressions on the surface of the capsule. No lesion was seen in other organs grossly.

Histopathological examination of the formalin-fixed liver under haematoxylin and eosin stain revealed numerous enormously enlarged intrahepatic bile ducts in the portal tracts with massive lymphocytic cell infiltration (Fig. 1). Under higher magnification, hyperplasia of the intrahepatic biliary epithelium was observed causing papillary projections or folding into the bile duct lumen (Fig. 2). Various stages of the gametocytes of coccidia were seen intracellularly in the biliary epithelium. The pus-like materials in the bile duct lumen consisted of desquamated epithelial cells, gametocytes and oocysts (Fig. 3). These microscopic lesions are characteristic of hepatic coccidiosis caused by *Eimeria stiedai* (Jones and Hunts, 1983).

The liver specimen in ice was also submitted for parasitological examination. However, due to autolysis of the organs, coccidia oocysts were not observed from the liver. No pathogenic bacteria were isolated from the liver on cultural studies. Based on the gross and microscopic lesions, the case was diagnosed as hepatic coccidiosis.

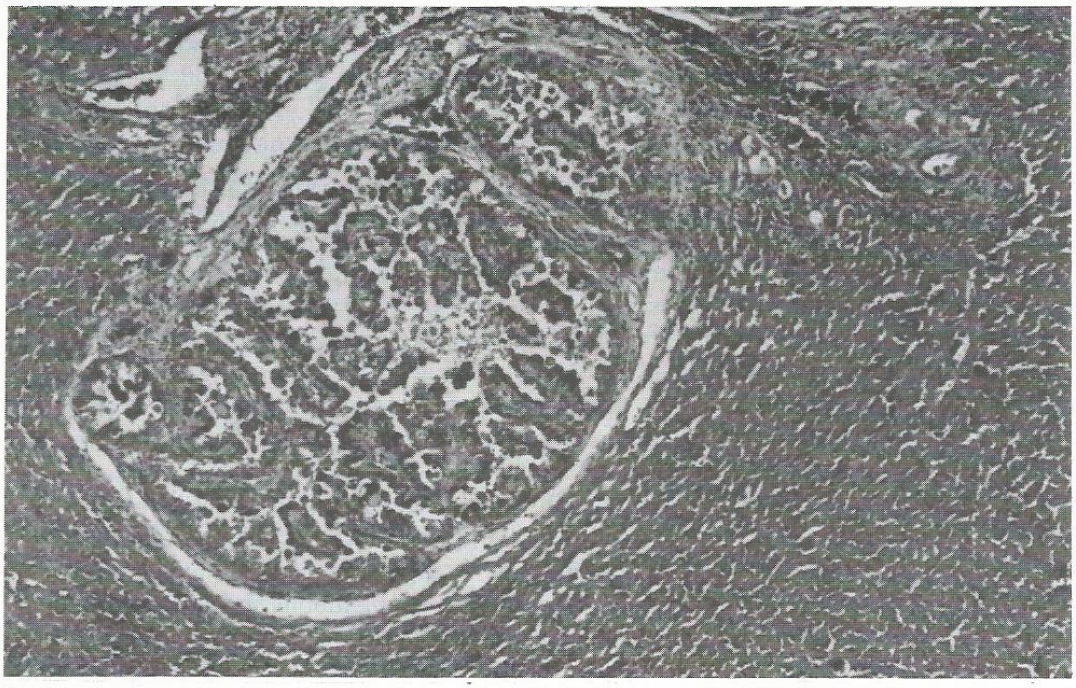

FIG. 1: Liver section showing an enormously enlarged intrahepatic bile duct in the portal tract with massive lymphocytic cells infiltration. (HE x 20)

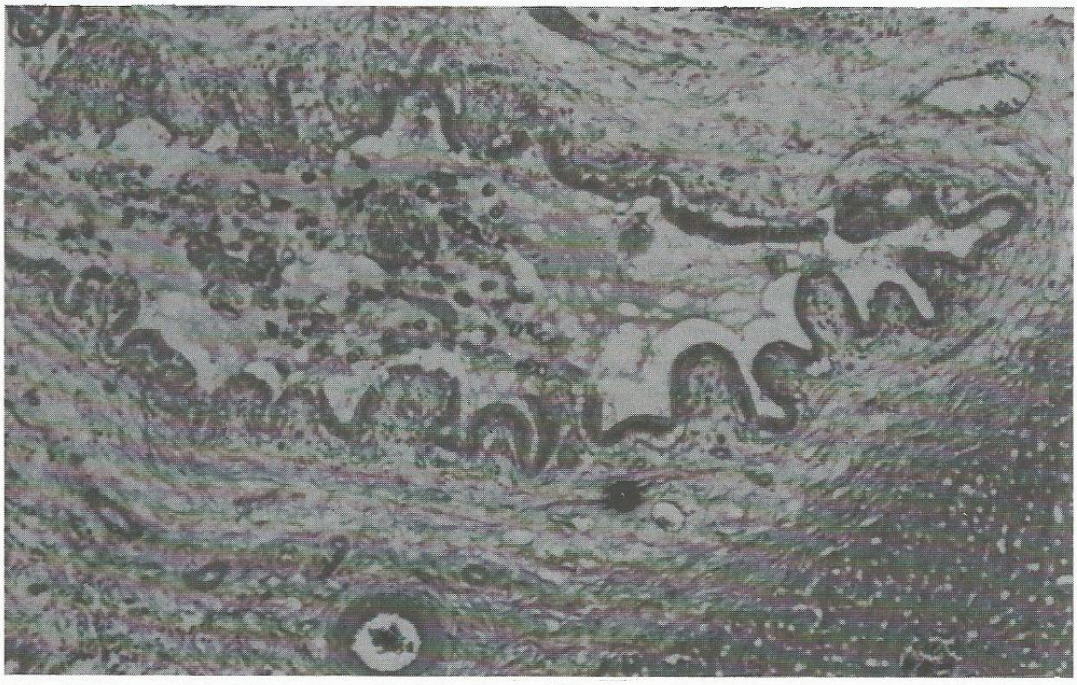

FIG. 2: Hyperplasia of intrahepatic biliary epithelium in liver causing papillary projection into the bile duct lumen. Pus-like materials in the lumen consisted of desquamated epithelial cells, gametocytes and oocysts. (HE x 50)

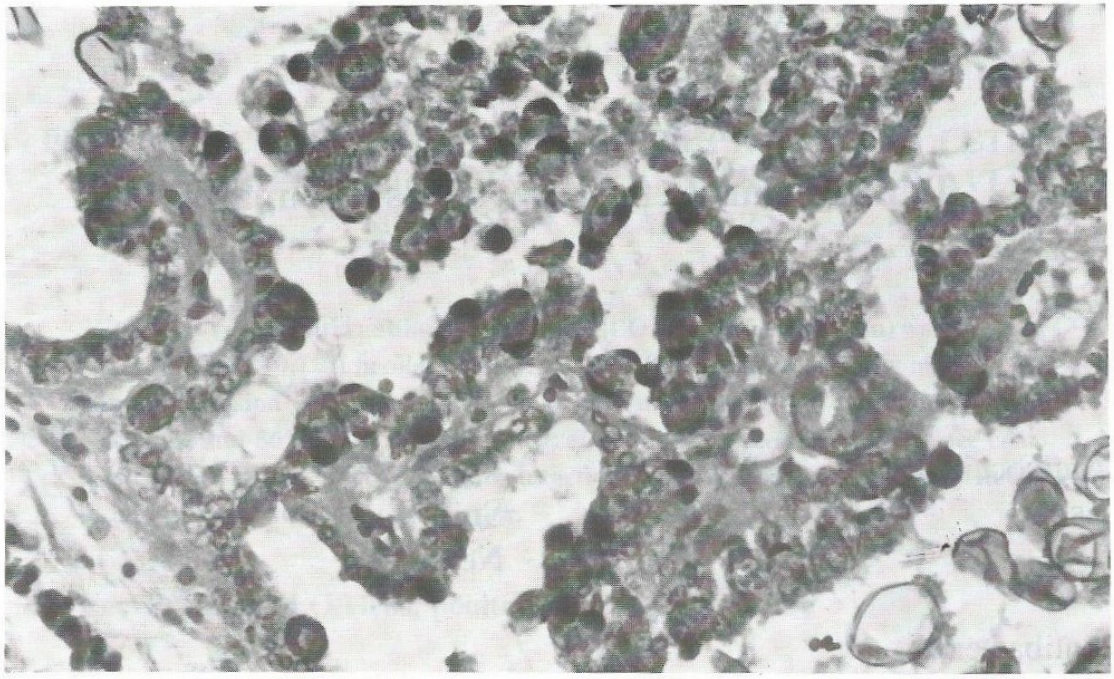

FIG. 3: Hyperplasia of intrahepatic biliary epithelium in liver of a rabbit infected with *Eimeria stiedae*. Gametocytes and oocysts were seen. (HE x 100)

ONG B.L. and NAZIRA, M.
Veterinary Diagnostic Laboratory
25100 Kuantan, Pahang, Malaysia.

REFERENCES

JONES, T.C and HUNT, R.D. (1983). Veterinary Pathology. 5th. edn., p 107 and p. 725. Lea and Febiger.

SOULSBY, E.J.L. (1982). Helminths, Arthropods and Protozoa of Domesticated Animals. p 660 - 661. Bailliere Tindall, London.

RINGKASAN

KES KOKSIDIOSIS HEPAR DALAM ARNAB

Kes koksidiosis hepar dalam dua ekor arnab dihuraikan. Lesi-lesi khusus bagi penyakit ini telah dilihat pada hati secara matakasar dan juga histopatologi.