J. Vet. Malaysia (2015) 27 (1):12-15

Case report

PLASTRON OSTEOTOMY IN THE MANAGEMENT OF FISHING HOOK INGESTION IN A MALAYAN BOX TURTLE (*Cuora ambonensis*)

C.A. Azlan[1*], M.H. Saw[2], R. Noorshimah[2], E.H.C. Cheah[1], J.L. Lam[1] and N. Mohd Jefri[1]

[1]*Faculty of Veterinary Medicine, Universiti Putra Malaysia, UPM Serdang, Selangor, Malaysia.*
[2]*University Veterinary Hospital, Faculty of Veterinary Medicine, Universiti Putra Malaysia, UPM Serdang, Malaysia*

SUMMARY

An adult male Malayan box turtle was diagnosed with foreign body obstruction of fishing hook. Upon presentation, the animal had pale mucous membrane and fishing line protruding out from the oral cavity. Diagnosis of foreign body ingestion was based on plain radiograph where the fishing hook was evidenced on the lateral and ventrodorsal radiographic view. Plastron osteotomy surgical removal was performed after endoscopy guided forcep removal failed. Procedures were carried out under the injectable anesthesia using a combination of ketamine and xylazine hydrochloride. Antibiotic, anti-inflammatory and parenteral fluid therapy was given pre and post-surgically as medical treatment and stabilisation.

Keywords: Malayan box turtle, foreign body obstruction, fishing hook, plastron osteotomy

INTRODUCTION

Malayan box turtle (*Cuora ambonensis*) is categorised under the class of Reptilia, order of Testudines and family of Betaguridae (Rummler and Fritz, 1991). Their native distribution includes north eastern India and Bangladesh to south eastern Asia especially Malaysian Peninsula, Borneo, Sumatra and Java (Fritz and Havas, 2007). According to The International Union for The Conservation of Nature (IUCN) Red List of Threatened Species, Malayan box turtle is listed as vulnerable (Asian Turtle Trade Working Group, 2000). Being semi-aquatic, the natural habitat is a low-land freshwater area up to 500 m above sea level. Malayan box turtle has several distinctive physical characteristics. They have dome-shape carapace with brown to dark coloration and distinguishable yellow stripes along the sides of head and neck along with black pigmentation and a hinge of plastron (Rummler and Fritz, 1991).

Over 260 species of mammals, turtles, fish, inverterbrates and birds have been reported to ingest or trapped in plastic debris. These impaired their movement, feeding, reproductive performance, injuries such as lacerations and ulcers and increased mortality (Derraik, 2002; Laist, 1997). Ingestion of fishing line can affected the normal intestinal function where different parts of the digestive tract pull at different ends of the line. Eventually digesta are unable to pass through the tract due to the gut gathering along the length of the line (Bjorndal *et al.*, 1994).

CASE REPORT

A male adult Malayan box turtle weighing 0.95 kg was presented to University Veterinary Hospital with the complaint of swallowing fishing line. Three days before presentation, it was found trapped in fishing net and a fishing line was protruding from his mouth. Since it was recovered, it was inappetence. Physical examination revealed pale oral mucous membrane and lethargy with minimal responsive. However, at the point of presentation, the fishing line was not observed. Radiological examination was performed with both lateral and ventrodorsal (VD) views were taken with radiological findings of radiopaque foreign body resembling fishing hook measuring 3 cm found in the coelomic cavity (Figure 1). Thus, the radiological diagnosis of fishing hook ingestion was made.

The turtle was stabilised with 3 ml 0.9% sodium chloride solution administered subcutaneously, twice a day for 3 consecutive days. The initial plan was to perform endoscopic-guided removal of the hook with forceps, under sedation using 30 mg/kg ketamine hydrochloride (Ilium Ketamil®, Troy Laboratories, Australia) intramuscularly. A fishing line was visible in the upper gastrointestinal tract. However, due to excessive gut secretion, fishing hook was invisible and the procedure was aborted. Surgical approach of plastron osteotomy was then performed to remove the foreign body. Patient was induced with a combination of ketamine hydrochloride (50 mg/kg, Ilium Ketamil®, Troy Laboratories, Australia) and xylazine hydrochloride (20 mg/kg, Ilium Xylazil-20®, Troy Laboratories, Australia) where 0.1 mg/kg were administered intramuscularly and turtle was maintained with ketamine hydrochloride. The surgical plane of anaesthesia was determined by the absence reaction to stimuli, loss of movement, the head and neck become flaccid. The respiratory was monitored by epiglottis opening movement. Breathing below than 4 breathe/minute warrant immediate intubation. After surgical preparation, the turtle was placed on dorsal recumbency and Opsite® (Smith& Nephew®, London, UK) patches were applied at the borders of designated plastron. Warm water bag was placed on both side of the turtle to keep chelonians warm (Figure 2). A dental burr was used to transect the plastron at the craniomedial area according to the most appropriate location of the hook, to form a rectangular osteotomy flap measuring 3 cm x 4 cm

**Corresponding author: Dr Azlan Che Amat (C.A. Azlan);*
Phone no.: +60173433811; Email: azlancheamat@gmail.com

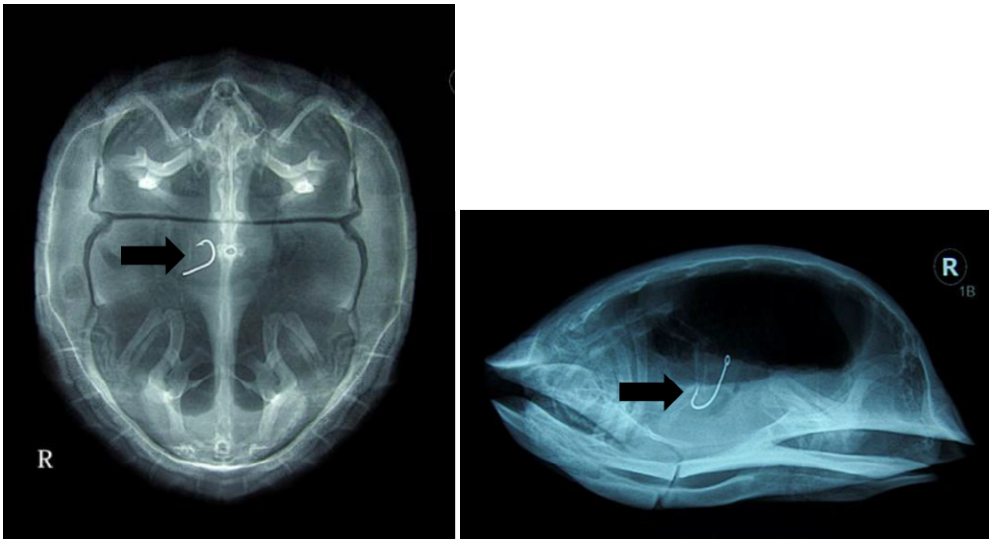

Figure 1. Both lateral (right) and ventral dorsal (left) views of radiograph revealed solid radiopaque foreign body in the coelomic cavity.



Figure 2. Masking tape was placed over the cranial and caudal end with warm water bags at the side. Dental burr was used to drill the plastron in rectangular shape measuring 3 cm x 4cm (*upper left*). After osteotomy flap removal, coeliotomy was performed along the midline to expose the coelomic cavity (*upper right*). Enterotomy was performed at anti-mesentric region after location the site of obstruction (*lower left*). Rusty fishing hook measuring 3 cm and fishing line measuring 15 cm in length were removed from the small intestine (*lower right*). The head position is on the right side.

(Figure 2). During drilling, saline drops was used to cool down the drilling site to prevent heat induced necrosis. Scalpel blade no.15 was used to separate the muscle attaching to the plastron flap and on dry sterile gauze. A stab incision was made on the coelomic membrane and the incision was extended 3 cm along the midline with scalpel blade No.15 to expose the coelomic cavity (Figure 2). The fishing hook was located *in situ* by using a spay hook and identified through a visibility on the serosal surface and upon palpation of metal-like material. Enterotomy was performed at anti-mesenteric region with a placement of stay suture. The rusty fishing hook approximately 3 cm in length and fishing line were removed from the small intestine (Figure 2). The gastrointestinal tract was thoroughly inspected for other perforation before closure. Enterotomy site was closed with 2-0 Vicryl® (Ethicon®, Somerville, USA) simple continuous pattern. Prior closing, the cavity was lavaged with 0.9% sodium chloride solution and 50 mg/kg metronidazole (Flagyl®, J.B. Chemicals & Pharmaceutical Ltd, India) and the intracoelomic enterotomy was closed with 2-0 Vicryl® simple continuous pattern. For plastron closure, 4 holes were made with dental burr on the midpoint of each side of osteotomy flap. The same holes were made on the intact plastron corresponding to the hole of osteotomy flap. Ethilon® 1-0 nylon non-absorbable suture material (Ethicon®, Somerville, USA) was used to ligate through the corresponding pairs of holes. The turtle was bandage with gauze and self-adhesive bandage Coban™ (3M™, Minnesota, USA) bandage over the surgical site. Intermittant Positive Pressure Ventilation (IPPV) at the rate of 1 breath/min was performed for 1 h due to weak respiration post-surgically. Warm water bags were used to keep the patient warm post-surgery.

Post-surgical medication regime were 10 mg/kg enrofloxacin (Baytril®10%, Bayer, Germany) once a day, 0.2 mg/kg meloxicam (Metacam®, Boehringer Ingelheim, USA) once a day and 0.9% sodium chloride twice a day administered subcutaneously for 2 days. On the first 2 days post-surgery, the patient was very weak and spent most of the time hiding in the shell thus making assessment of the patient's condition very difficult. Unfortunately, the patient died in the morning on day 3 post-surgery.

DISCUSSION

Aquatic turtles are prone to ingest variety of foreign objects. Diagnosis can be challenging as common presentation with foreign body obstruction can be simply be inappetence and weight loss (Walter *et al.,* 2003). In some cases, ingestion of foreign materials by turtles passed through the gastrointestinal tract without causing clinical problems. However on the other hand, perforation can occur resulting in serious consequences such as oesophagitis, stricture formation causing regurgitation, cellulitis, peritonitis and potentially death (Hyland, 2003). Radiography is necessary to confirm the diagnosis. Sometimes the ingested foreign body does not appear on the radiograph, thus a barium contrast study is necessary to make the diagnosis (Walter *et al.*, 2003). However, in this case, the radiograph is evident enough to diagnose the foreign body obstruction as the ingested object was radiopaque.

A number of approaches are available to remove the foreign body namely plastron osteotomy, pre-femoral approach and endoscopy guided forcep removal. The later was a failure due to excessive gut secretion. Thus surgical approach was considered for this case. Plastron osteotomy is preferred over pre-femoral approach because the approach provides a wider access to the gastrointestinal tract in order to locate the obstruction site. However, it would take a longer time to heal and may inflict more post-surgical pain compared to pre-femoral approach (Hernandez-Divers, 2006). The approach to the left axillary region coeliotomy was preferred in turtles with fish hook ingested into the stomach. If the foreign body was located in the pyloric of the stomach or intestine coeliotomy through the right or left pre-femoral fossa could be performed (Di Bello *et al*., 2006 and 2013). These two useful methods enabled the approach into the coelomic cavity with minimally invasiveness, easy and satisfactory survival rates. Nonetheless, we performed plastron osteotomy based on the capability to use this approach and surgeon preference which takes a consideration to have a wider access to the coelomic cavity. In addition, the axillary or pre-femoral coeliotomy approach would be much easier to perform with a suitable apparatus such as self-retaining retractors (e.g. Lonestar retractor) (Alworth *et al*., 2011). In the case of plastron osteotomy in sea turtle with intestinal volvulus and stricture, screws and wires were used to oppose the osteotomy sites and epoxy was applied to improve bonding site (Helmick *et al*., 2000). However we managed the osteotomy by using non-absorbable suture material and protected the area using bandage and preventing contact with water. Endoscopic guided may be useful to visualise and remove the foreign object at the upper tract such as oesophagus. Surgical by lateral neck approach also have been used to remove fish hook from the oesophagus in turtle (Hyland, 2003). Excessive gut secretion as seen in this case reduced the visibility during endoscopic procedure, thus the use of parasympathetic nervous system inhibition drugs such as atrophine sulphate may reduce the activity of salivary and mucus glands.

Injectable anaesthesia with ketamine and xylazine combination was chosen because of ketamine has its high therapeutic range, wide safety margin, commonly used in reptiles and combination with xylazine will reduced the dose of ketamine (Bouts and Gasthuys, 2002). In addition, the characteristics of this turtle to box itself completely within its shell eventually, anesthetic induction was a very challenging choice. Thus, when we were able to retract the limbs, an injectable anesthesia is preferred and maintained with the same regime during the procedure. Intraoperative monitoring in turtles can be very challenging without proper apparatus. According to Mosley (2005), observation of respiratory movement and auscultation of heart in chelonian can be difficult because of the interference of the plastron or carapace. Cardiovascular assessment may be achieved by using suitable equipment such as esophageal stethoscope, ultrasonic Doppler device or electrocardiograph. The

reptiles are suggestive to be in surgical plane when there are absence of muscle tone and voluntary movements. The turtle should be monitored closely during recovery because it can be prolonged (Mosley, 2005). Thermal support is essential since the body temperatures in reptiles are correlated with external environment. During anaesthesia, preferred body temperature is regulated by warm water blanket, warm water bottles or warm forced air (Mosley, 2005). Warm water bag was used as a thermal regulator during and post-surgery in this turtle.

Postoperative care is very important to ensure wound healing and health of the patient. Dehydration is a common clinical problem in sick turtles and is often associated with anorexia. Therefore, hydration is important and can be achieved by daily administration of subcutaneous fluids or access to deep water (Quesenberry and Hillyer, 1993) that was delivered in this case. Deep water allows partial submergence and absorption of water through the cloaca. The turtle's access to deep water was limited initially as it was considered detrimental to the wound healing (Boyer and Boyer, 1996). The other important management is to provide preferred optimal environment. Ideal temperature zone for aquatic and semi-aquatic turtles is 25°C to 35°C°. In this case, warm water bag was used to maintain the optimal temperature and to also facilitate the recovery of the turtle.

Based on data and clinical experience in reptiles, Hernandez-Divers (2006) stated that analgesic management with non-steroidal anti-inflammatory drugs particularly with meloxicam gives a good effect with no adverse reaction, well tolerated with high therapeutic index and available in both injectable and oral suspension. Enrofloxacin was used in this case based on commonly antimicrobial used in reptiles due to its activity against gram-positive and gram-negative aerobic bacteria and less adverse effect, except known for causing local irritation and soft tissue necrosis on injection site (Prezant*et al*., 1994; Raphael *et al*., 1994; Jacobson, 1999). Considering the clinical condition during admission, lack of response during recovery and with the addition of the possibilities of the intestinal perforation, septic infection may complicate the outcome and could be the causes leading to death of this turtle.

CONCLUSION

Foreign body obstruction with perforation in gastrointestinal tract, clinical presentation during admitted and unresponsive during recovery can cause death as suspected in this case. A few option of management can be applied but plastron osteotomy approach was chosen due to better surgical access compared to others. Post-surgical management is important especially post-recovery monitoring, pain management, the environmental temperature, hygiene, hydration and feeding.

ACKNOWLEGEMENTS

The author would like to thanks Large Animal Unit and Small Animal Surgery Unit, University Veterinary Hospital (UVH), Faculty of Veterinary Medicine, Universiti Putra Malaysia for the assistance and support in this case.

CONFLICT OF INTEREST

No conflict of interest.

REFERENCES

Alworth, L.C., Hernandez, S.M. and Divers, S.J. (2011). Laboratory reptile surgery: Principles and techniques. Journal of American Association of Laboratory Animal Science. 50(1): 11–26.

Asian Turtle Trade Working Group (2000). Cuoraamboinensis.The IUCN Red List of Threatened Species.Version 2014. 2. <www.iucnredlist.org>. Assessed on 08 October 2014.

Bjorndal, K.A., Bolten, A.B. and Lagueux, C.J. (1994). Ingestion of marine debris by juvenile sea turtles in coastal Florida habitats. Marine Pollution Bulletin. 28: 154-158.

Boyer, T.H. and Boyer, T.M. (1996).Turtles, tortoises, and terrapins. In: Reptile medicine and surgery. Mader, D.R. (ed). WB Saunders, Philadelphia. 61-78.

Bouts, T. and Gasthuys, F. (2002).Anaesthesia in reptiles. Part 1: injection anesthesia. Vlaams Diergeneeskundig Tijdschrift. 71: 183-194.

Derraik, J.G.B. (2002). The pollution of the marine environment by plastic debris: a review. Marine Pollution Bulletin.44: 842-852.

Di Bello, A., Valastro, C. Freggi, D., Lai, O.R., Crescenzo, G. and Franchini, D. (2013). Surgical treatment of injuries caused by fishing gear in the intracoelomic digestive tract of sea turtles. Diseases of Aquatic Organisms. 106: 93–102.

Di Bello, A., Valastro, C. and Staffieri, F. (2006). Surgical approach to the coelomic cavity through the axillary and inguinal regions in sea turtles. Journal of American Veterinary Medical Association. 228(6): 922-925.

Fritz, U. and Havas, P. (2007). Checklist of chelonians of the world.Vertebrate Zoology. 57:149-368.

Helmick, K.E., Bennett, A., Ginn, P., DiMarco, N., Beaverand, D.P. and Dennis, P.M. (2000). Intestinal volvulus and stricture associated with a leiomyoma in a green turtle (Cheloniamydas). Journal of Zoo and Wildlife Medicine. 31 (2): 221-227.

Hernandez-Divers, S.J. (2006). Reptile coeliotomy: a vital technique to master. In: The Proceedings of the North American Veterinary Conference, Orlando, Florida, volume 20: 1614-1618.

Hyland, R.J. (2003). Surgical removal of a fish hook from the oesophagus of a turtle.Australian Veterinary Journal. 80(1-2): 54-56.

Jacobson, E., Gronwall, R., Maxwell, L., Merrit, K. and Harman, G. (1999). Plasma concentrations of enrofloxacin after single-dose oral administration in loggerhead sea turtles (Carettacaretta). Journal of Zoo and Wildlife Medicine. 36(4): 628–634

Laist, D.W. (1997). Impacts of marine debris: entanglement of marine life in marine debris including a comprehensive list of species with entanglement and ingestion records. In: Marine debris: sources, impacts, and solutions. Coe, J.M. and Rogers, D.B. (eds.). Springer-Verlag, New York, pp. 99-140.

Mosley, C.A.E. (2005). Anaesthesia and analgesia in reptiles.Seminars in Avian and Exotic Pet Medicine. 14(4): 243-262.

Prezant, R. M., Isaza, I. and Jacobson, E.R. (1994). Plasma concentrations and dipsosition kinetics of enrofloxacin in gopher tortoises (Gopheruspolyphemus). Journal of Zoo and Wildlife Medicine. 25: 82–87.

Quesenberry, K.E. and Hillyer, E.V. (1993). Biology and medicine of turtles and tortoises.Veterinary Clinics of North American Small Animal Practice. 23: 1251-1270.

Raphael, B. L., Papich, M. and Cook, R.A. (1994). Pharmcokinetics of enrofloxacin after a single intramuscular injection in Indian star tortoises (Geocheloneelegans). Journal of Zoo Wildlife Medicine. 25: 88–94.

Rummler, H.J. and Fritz, U.(1991). Geographische variabilität der amboina scharnierschildkröte Cuora amboinensis mit Beschreibungeinerneuen Unterart, C.a. kamaroma. Salamandra. 27(1): 17-45.

Walter, J.,Rosskopf, J. and Shindo, M.K. (2003). Syndromes and conditions of commonly kept tortoise and turtle species.Seminars in Avian and Exotic Pet Medicine. 12 (3): 149-161.